



FINDINGS OF PELVIC ENDOMETRIOSIS AT TRANS VAGINAL US IMAGING



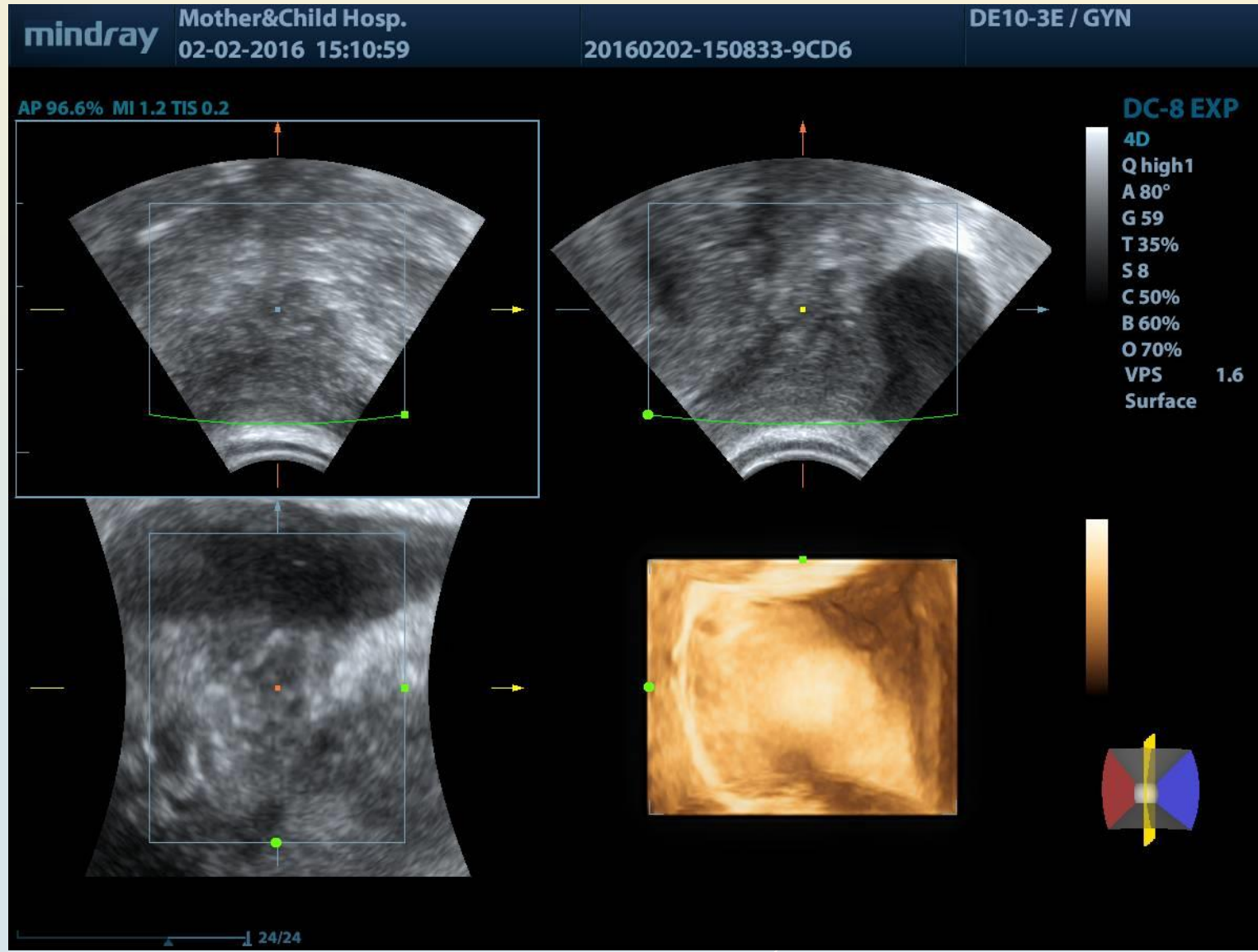
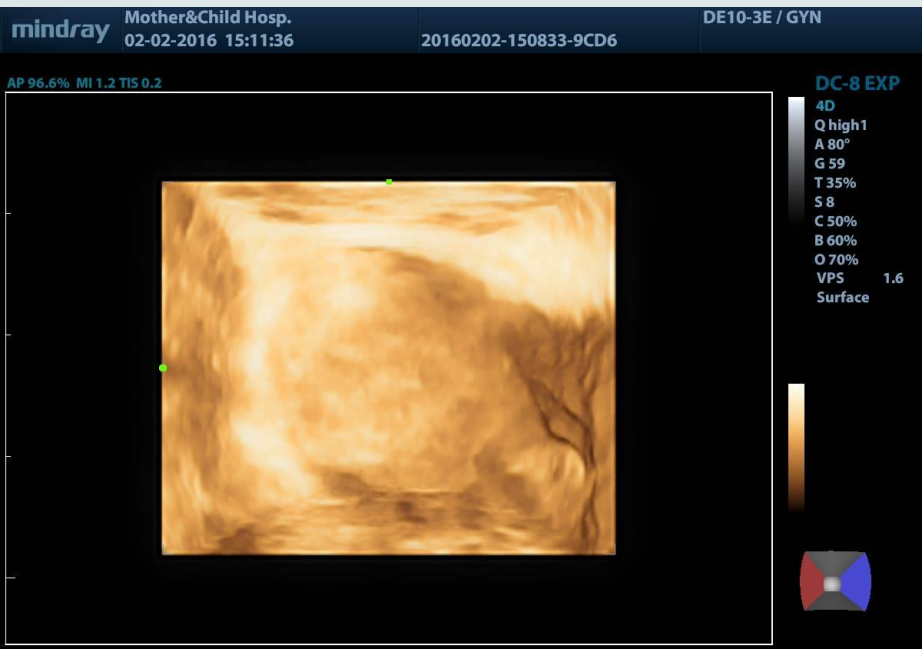
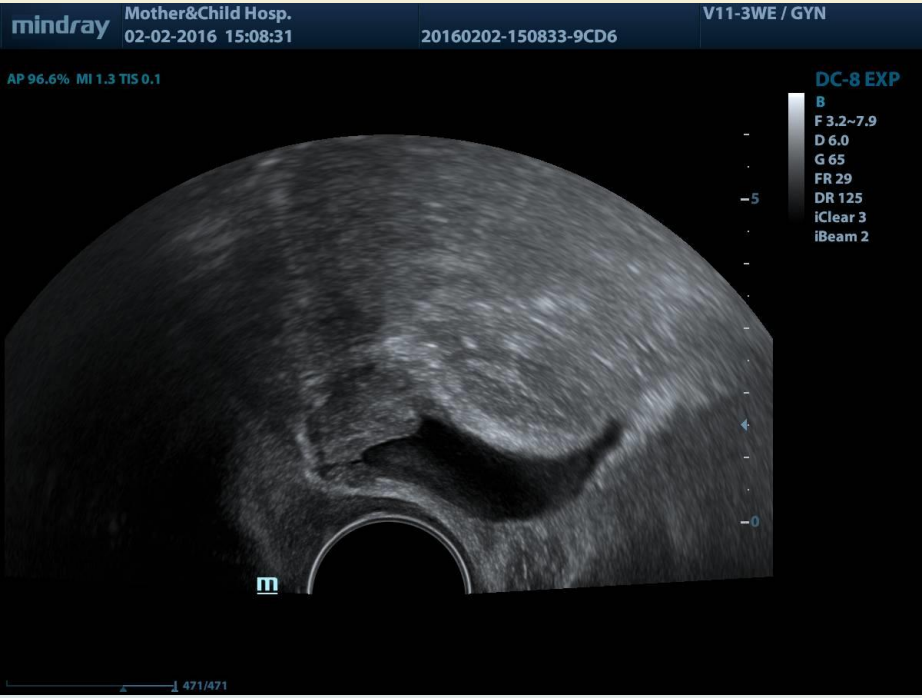- ▶ A definitive diagnosis of endometriosis is based on histologic confirmation of surgically resected lesions containing endometrial glands and stroma with various amounts of inflammation and fibrosis
- ▶ A presumptive diagnosis of deeply infiltrating endometriosis may be developed on the basis of imaging with transvaginal ultrasonography (US), transrectal US, rectal endoscopic US, or magnetic resonance (MR) imaging, all of which have been used for this purpose
- ▶ Collaboration between radiologists and gynecologists has enabled the achievement of high levels of diagnostic accuracy
- ▶ Trans vaginal US performed after bowel preparation should be the first-line imaging examination when the presence of endometriosis is suspected

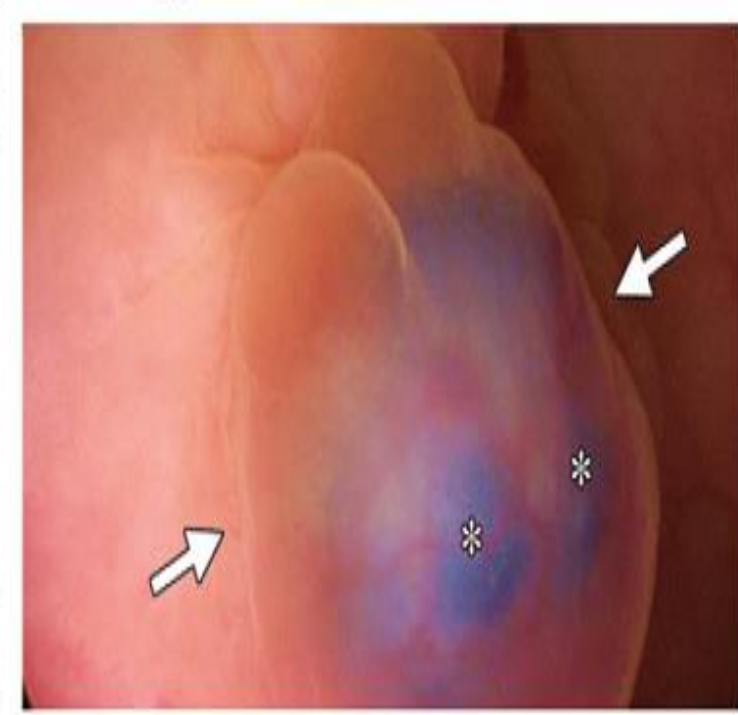
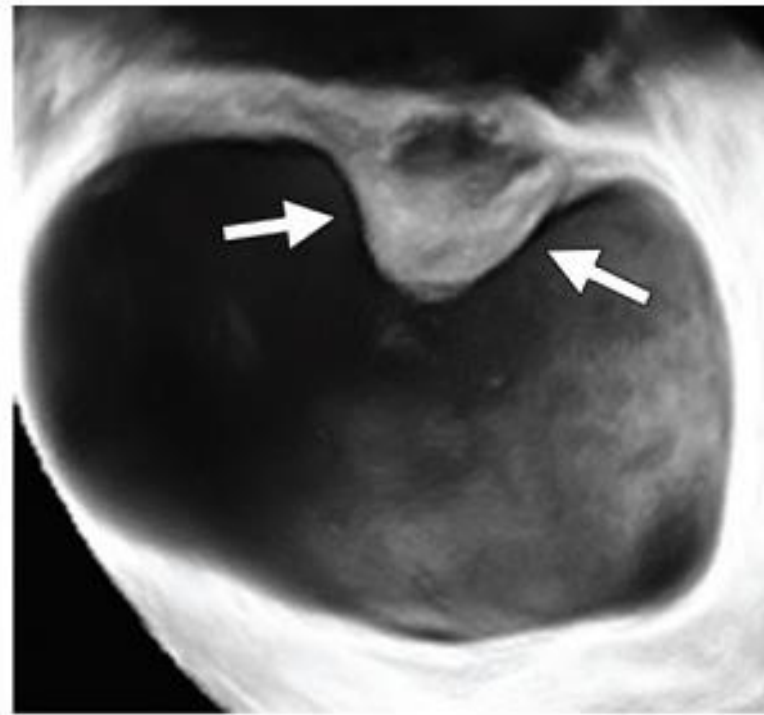
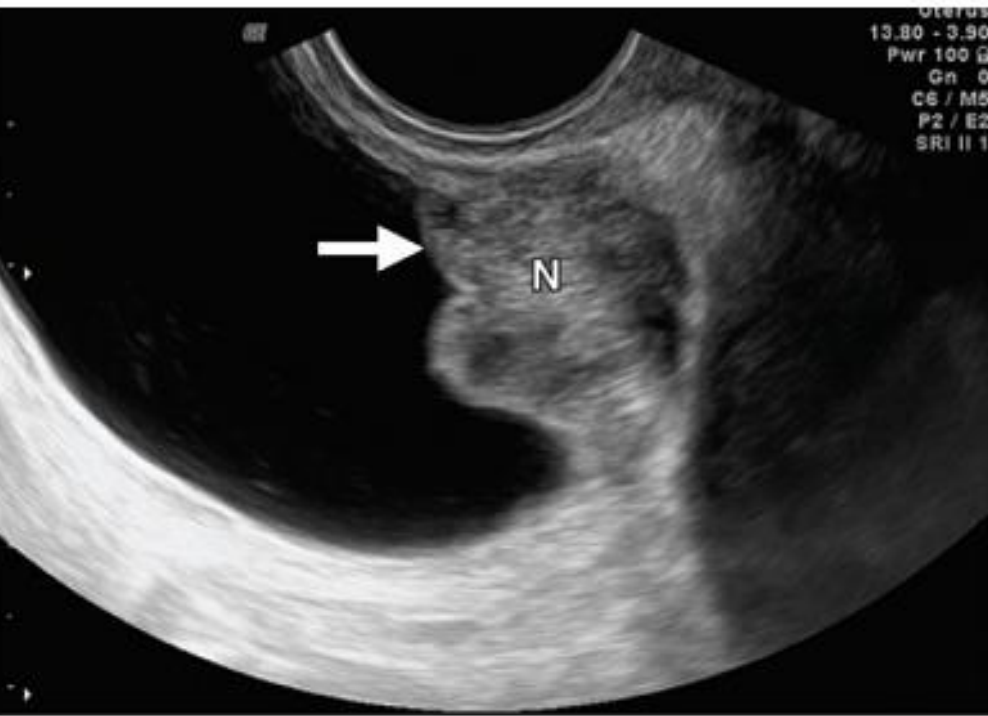
- ▶ several “modified TVS” techniques have been proposed such as saline contrast sono vaginography (SCSV), tenderness-guided-TV S (TG-TV S), rectal water contrast TV S (RWC-TV S), Rectal endo sonography and TV S sliding sign.
- ▶ TV S has a satisfactory specificity for all DIE sites, with values ranging from 88% (in case of vaginal and USL location) to 94% (PoD and bladder location). Data regarding TV S sensitivity are less favorable, since they range from 50% (for bladder and vagina locations) to 85% in RSE location.

- ▶ sonovaginography for the assessment of rectovaginal endometriosis, based on transvaginal ultrasonography combined with the introduction of saline solution to the vagina that creates an acoustic window between the transvaginal probe and the surrounding structures of the vagina.
- ▶ 'tenderness-guided' ultrasonography using an acoustic window between the transvaginal probe and the surrounding vaginal structures by increasing the amount of ultrasound gel inside the probe cover. In addition, because the endometriotic nodule itself can induce pain, they asked patients to indicate during the ultrasonographic examination which points felt tender under gentle pressure of the probe, and they paid particular attention to evaluate those sites. Using this approach, they obtained a specificity of 95% with a sensitivity of 90%

- ▶ Transvaginal US typically depicts an endometriotic implant in the bladder as a **solid hypoechoic nodule with regular or irregular contours that adheres to the posterior aspect of the bladder dome**, frequently at the midline
- ▶ Considering all techniques, we found a sensitivity of 55.5% _ 62.0% with higher rates reported for TG-TVS (97.4%) and lower rates for RES (16.7%), the investigators reported a sensitivity ranging between 16.7% and 83.3%, with a mean value of about 55%
- ▶ The overall value of the specificity is 94.2 with better rates reported for TG-TVS (97.4%) and inferior rates for RES (92.9%). Additionally, for TVS, the mean value was 93.5%

BLADDER ENDOMETRIOSIS



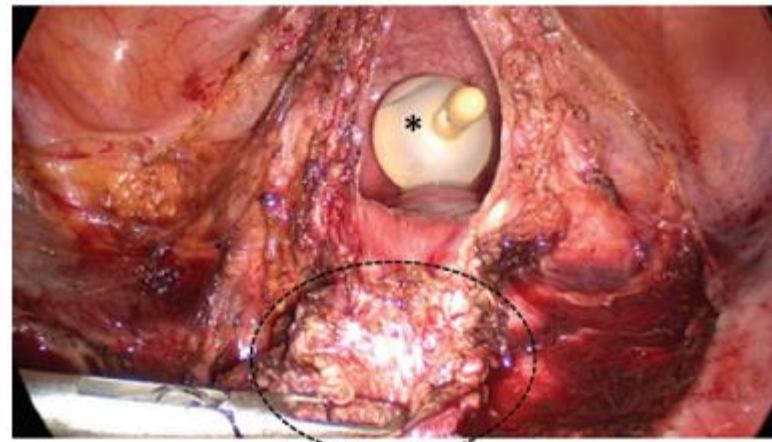
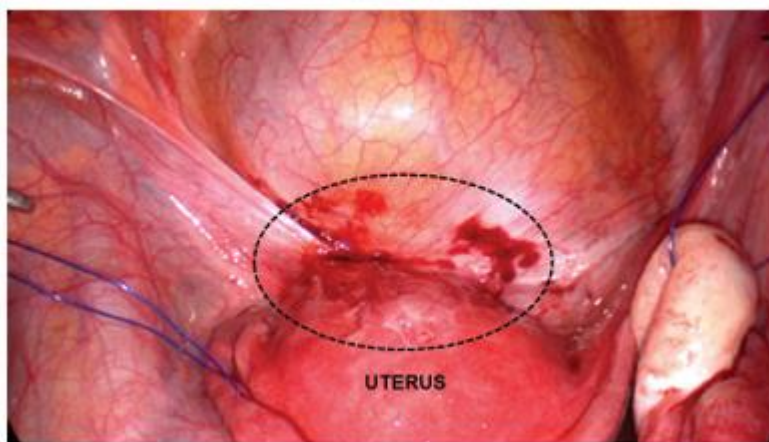
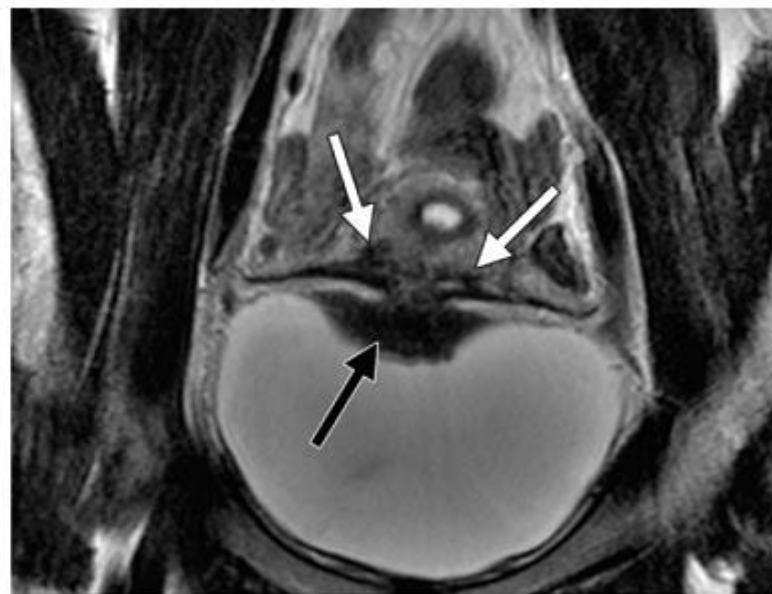
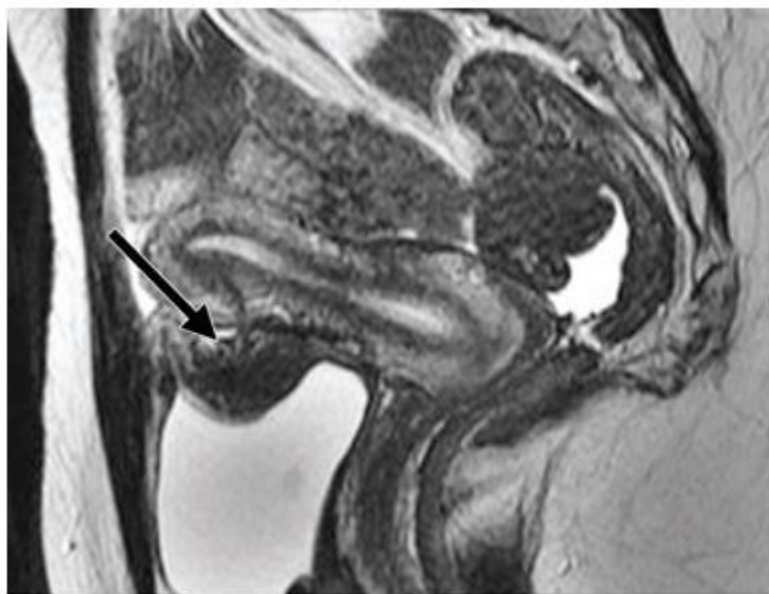


a.

b.

c.

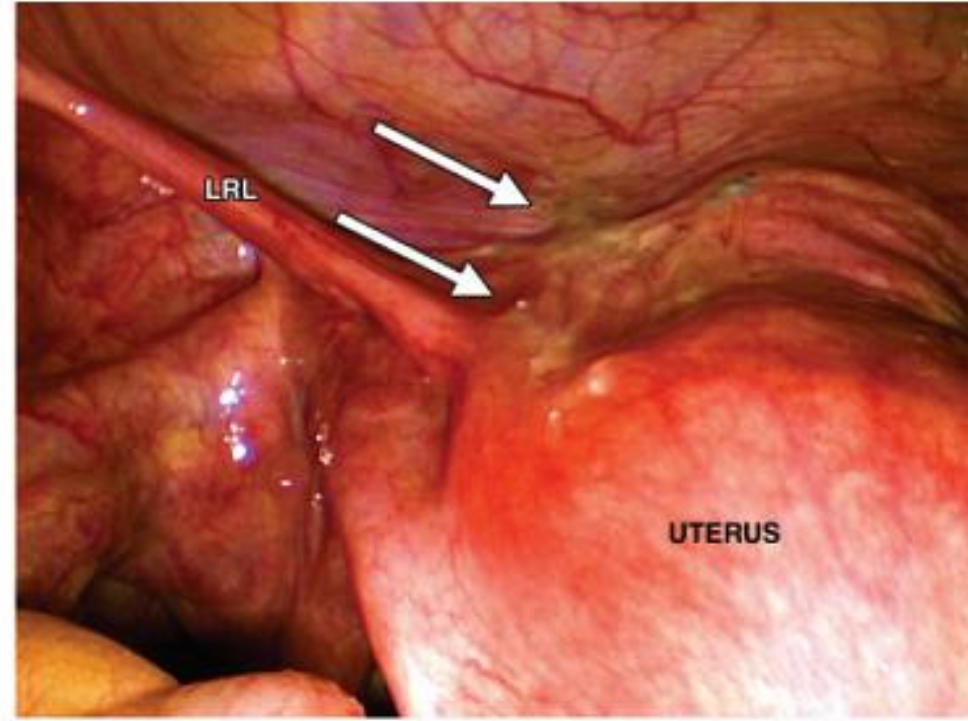
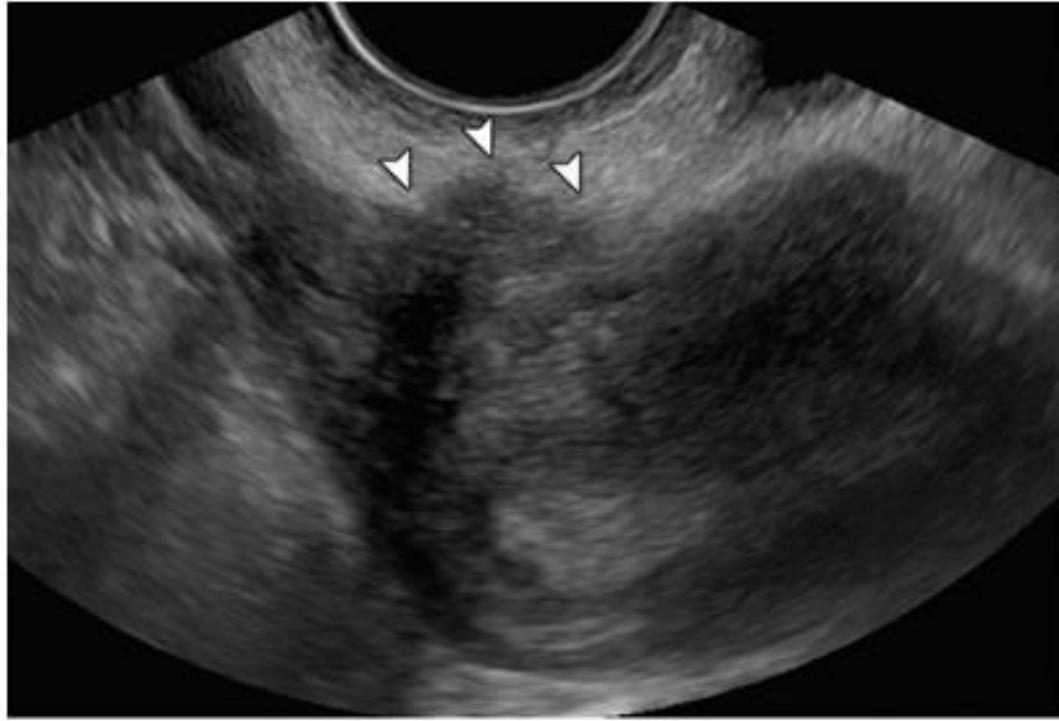
Bladder endometriosis in a 28-year-old woman. (a) Sagittal transvaginal US image shows a hypoechoic nodule (N) attached to the bladder wall and hypoechoic endometrial tissue infiltrating the detrusor muscle (arrow). (b) Three-dimensional transvaginal US image shows projection of the nodule (arrows) into the bladder lumen. (c) Magnified cystoscopic view of the same lesion (arrows) shows bluish spots (*) that represent tiny hemorrhagic foci.



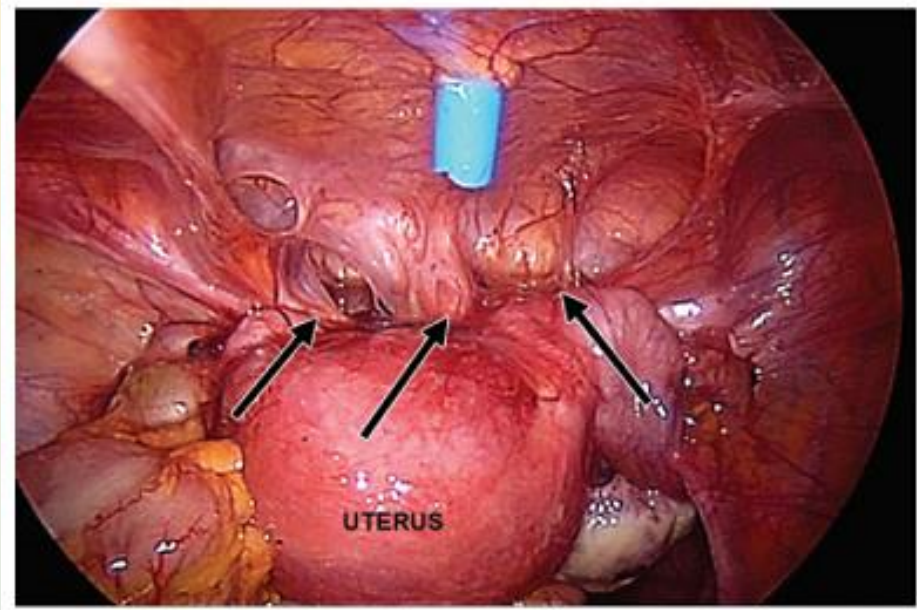
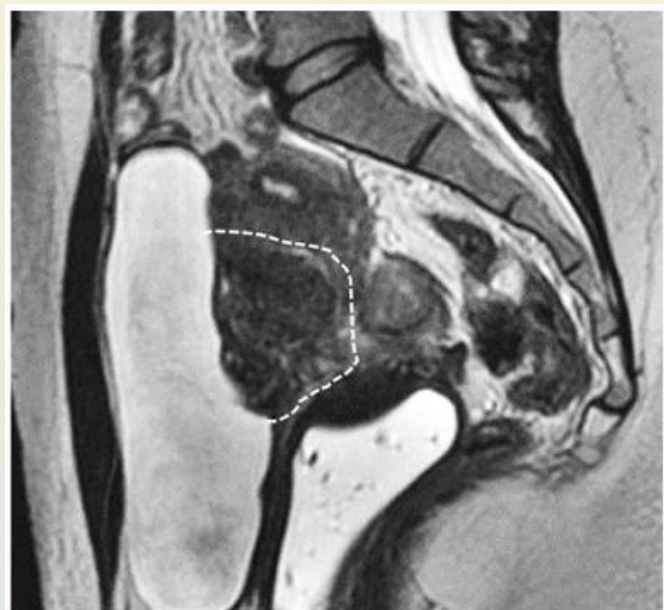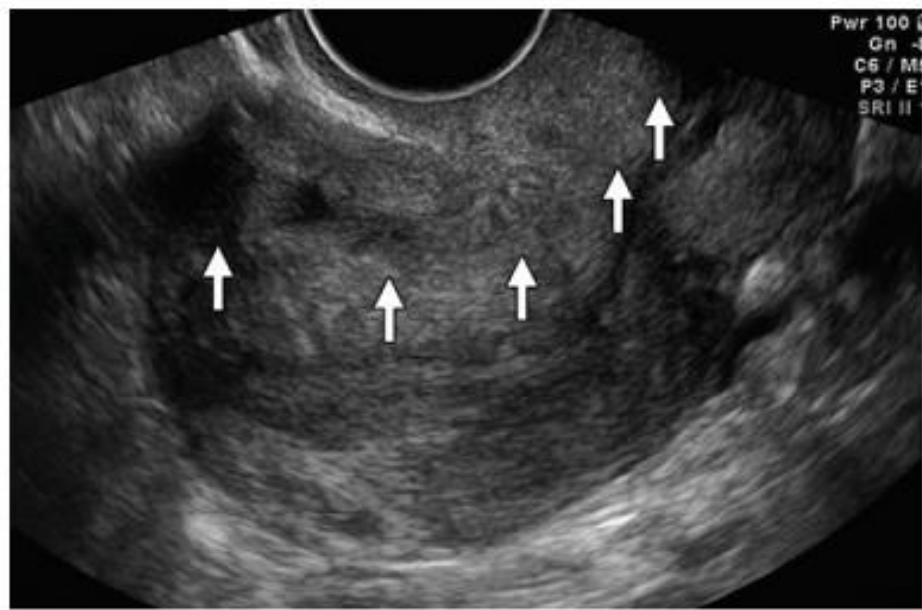
Bladder endometriosis in a 30-year-old woman with dysuria. Sagittal and coronal T2-weighted MR images show a well-defined low-signal-intensity bladder wall nodule (black arrow) projecting into the lumen. Thickening of the anterior uterine serosa (white arrows in b) Laparoscopic view shows retraction and distortion in the anterior compartment of the pelvis because of adhesions between the anterior uterine serosa and the vesicouterine peritoneum (dashed oval). Laparoscopic view obtained after resection shows the site of the nodule in the bladder wall (dashed oval). A catheter balloon (*) can be seen through the opened bladder dome

- ▶ Deeply infiltrating endometriotic lesions that involve the anterior uterine serosa and round ligament insertion sites have **an infiltrative pattern with indistinct margins**.
- ▶ At transvaginal US, these lesions **appear hypoechoic in comparison with the myometrium and usually contain multiple bright foci or small cystic areas**.
- ▶ The differential diagnosis of small round lesions, especially those located at the site of round ligament insertion, includes subserosal leiomyoma.
- ▶ Clues to the correct diagnosis of deeply infiltrating endometriotic lesions are their **indistinct margins in contrast with the circumscribed and well-defined margins of sub-serosal leiomyomas**, and the presence of **small cystic areas or bright punctate foci in endometriotic lesions**.

ENDOMETRIOSIS OF THE UTERINE SEROSA AND ROUND LIGAMENTS



Endometriosis of the anterior pelvic compartment in a 32-year-old woman. (a) Sagittal oblique trans-vaginal US image shows a hypoechoic endometriotic lesion (arrowheads) with irregular and ill-defined margins that has infiltrated the peritoneum near the insertion of the left round ligament. (b) Laparoscopic view depicts vesicouterine peritoneal infiltration (arrows) near the left round ligament (LRL)

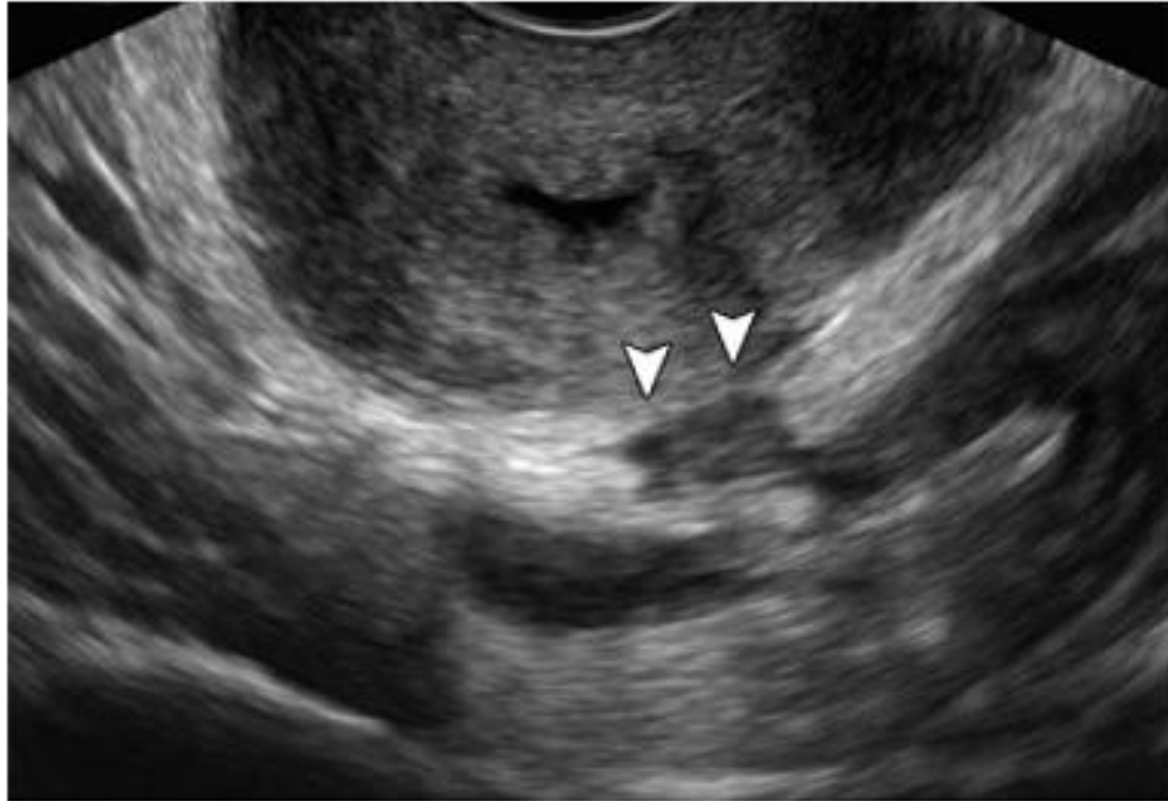


Extensive endometriosis in the anterior pelvic compartment in a 30-year-old woman. Sagittal transvaginal US image shows a region of heterogeneous hypoechogenicity with ill-defined margins (arrows), a finding indicative of endometrial infiltration of the peritoneum in the vesicouterine pouch. Sagittal T2-weighted MR images show extensive infiltration of the anterior uterine serosa and myometrium (area inside the dashed line) and posterior displacement of the uterus. Laparoscopic view depicts endometriotic implants (arrows) in the anterior pelvic compartment, with associated firm adhesions to the anterior abdominal wall.

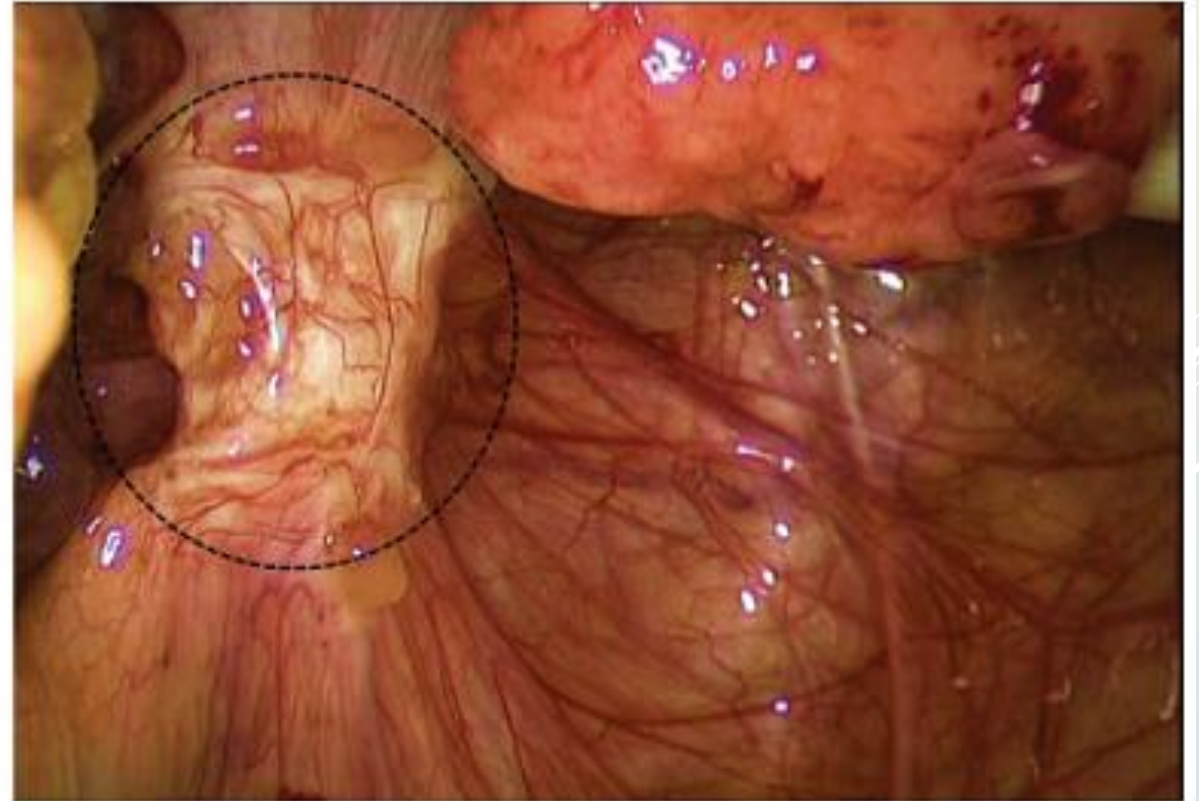
- ▶ The retrocervical region is commonly affected by deeply infiltrating endometriosis, and involvement of this region usually causes severe and painful symptoms ;.
- ▶ Morphologic abnormalities that may occur include asymmetry between the two ligaments, diffuse or localized thickening, and a nodule with a regular or stellate margin near the site of cervical uterosacral ligament insertion.
- ▶ Uterosacral ligament nodules commonly display a mixed echotexture due to anechoic or hypoechoic cystic areas within them at transvaginal US .

ENDOMETRIOSIS OF THE RETROCERVICAL REGION

Figure 7. Retrocervical endometriosis in a 26-year-old woman. **(a)** Axial transvaginal US image shows a small hypoechoic nodule (arrowheads) near the insertion of the left uterosacral ligament. **(b)** Laparoscopic view depicts focal infiltration and retraction of the left uterosacral ligament (dashed oval).



a.



b.

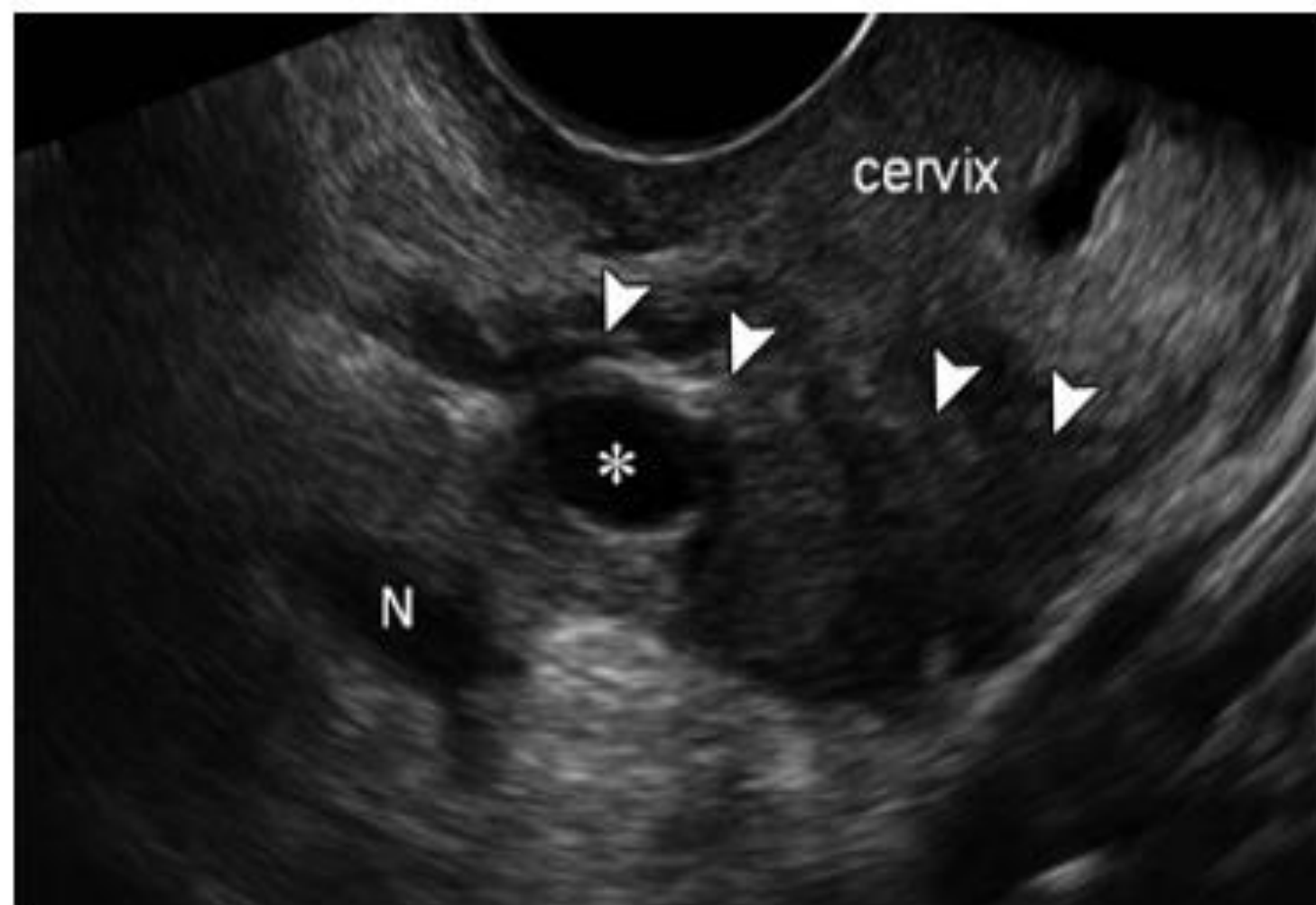
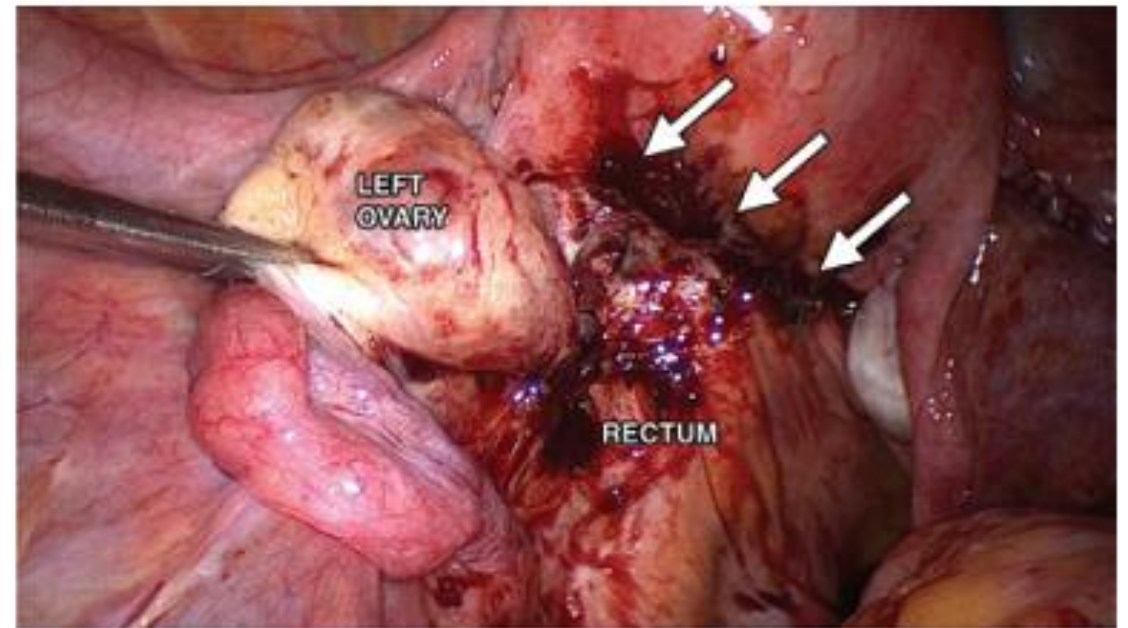
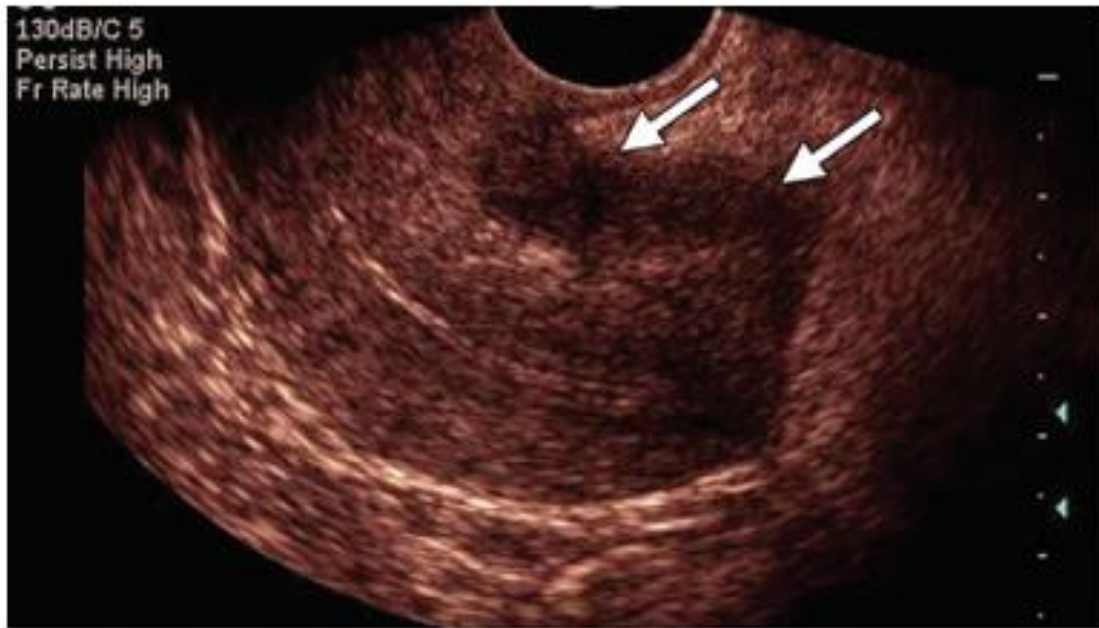

Figure 9. Retrocervical endometriosis in a 32-year-old woman. Axial oblique transvaginal US image shows a large lesion (arrowheads) with both solid and cystic components involving the right uterosacral ligament. The lesion contains a large round cyst (*). Another hypoechoic nodule (N) is seen attached to the anterior rectal wall.



a.

b.

Figure 11. Extensive endometriosis of the posterior pelvic compartment in a 27-year-old woman. **(a)** Sagittal transvaginal US image shows a hypoechoic lesion (arrows) with ill-defined margins covering and infiltrating the posterior uterine wall, from the fundus to the retrocervical region. **(b)** Laparoscopic view shows endometriotic tissue that has infiltrated the posterior uterine wall (arrows) and adheres to the anterior rectal wall. The left ovary is medially located and involved in the adhesive process.

- ▶ sensitivity of 49.7% _57.1%, with the highest rate reported for SCSV (88.9%) and the lowest for TVS sliding sign (40%). The remaining techniques showed a rate of about 50%, ranging from 49% to 50%
- ▶ an overall specificity of 68.9% _77.8% with a good rate reported for all techniques except for RES (49.5%)

USL DIE

AP 96.6% MI 1.3 TIS 0.1

DC-8 EXP

B

F 3.2~7.9

D 6.0

G 65

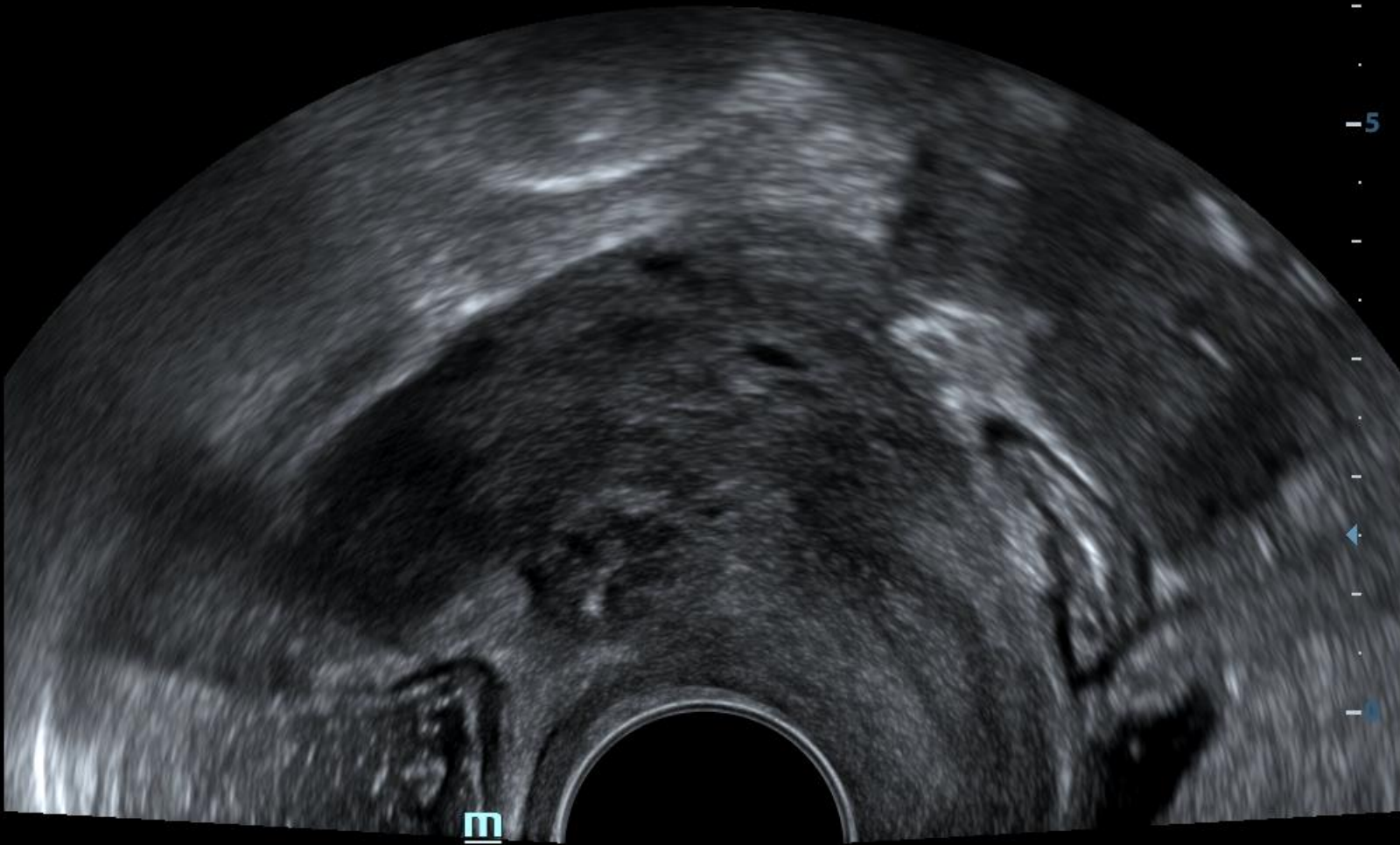FR 29

DR 125

iClear 3

iBeam 2

-5

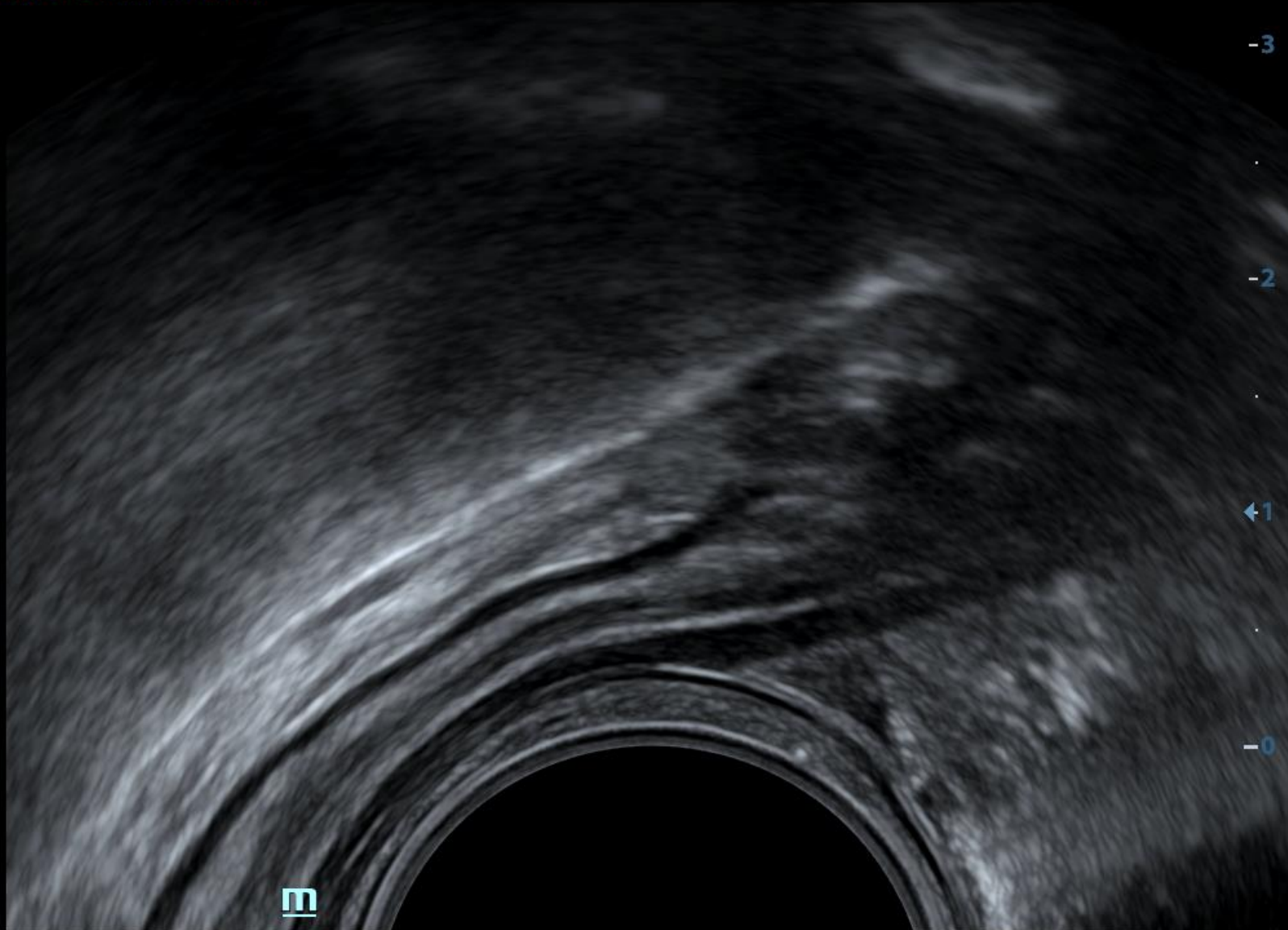


▶ NI USL

- ▶ sensitivity of 52.3% _80.5% with a better rate reported for both TVS **sliding sign** (83.3%) and RES (82%) and a worse rate for TVS (47.2%)
- ▶ the specificity overall value is 91.7% _ 94.9 , with a better rate **reported for RES** (98.4%) followed by TVS sliding sign (98.2%)

POD DIE

AP 96.6% MI 1.3 TIS 0.1



DC-8 EXP

B
F 3.2~7.9
D 3.5
G 65
FR 37
DR 125
Z 1.40
iClear 3
iBeam 2

-3

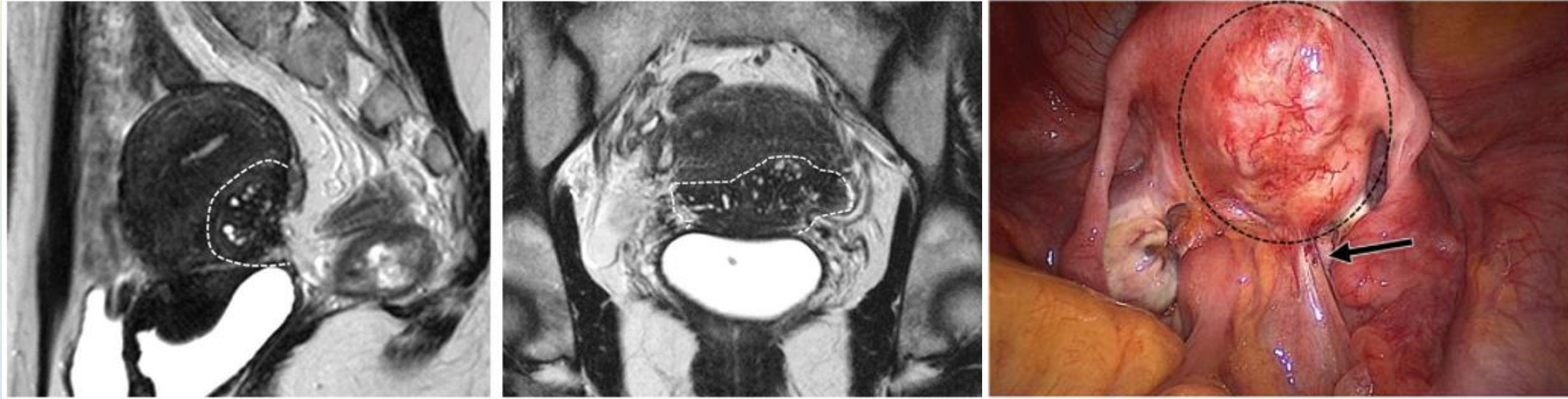
-2

←1

-0

▶ Sliding sign

- ▶ Another appearance of retrocervical lesions is that of **infiltrative tissue with indistinct margins that covers the posterior uterine serosa**, usually from the uterine fundus to the retrocervical region, frequently with associated uterine retractile retroflexion.
- ▶ The infiltrative tissue is characteristically **hypoechoic at transvaginal US** and shows marked low signal intensity on T2-weighted MR images. This pattern also usually **includes multiple bright internal foci or small cystic areas**.
- ▶ The differential diagnosis of retrocervical lesions includes peritoneal metastases, most commonly from gastrointestinal and ovarian malignancies
- ▶ The laparoscopic appearance of retrocervical deeply infiltrating endometriotic lesions is emblematic and easily recognized by the surgeon.



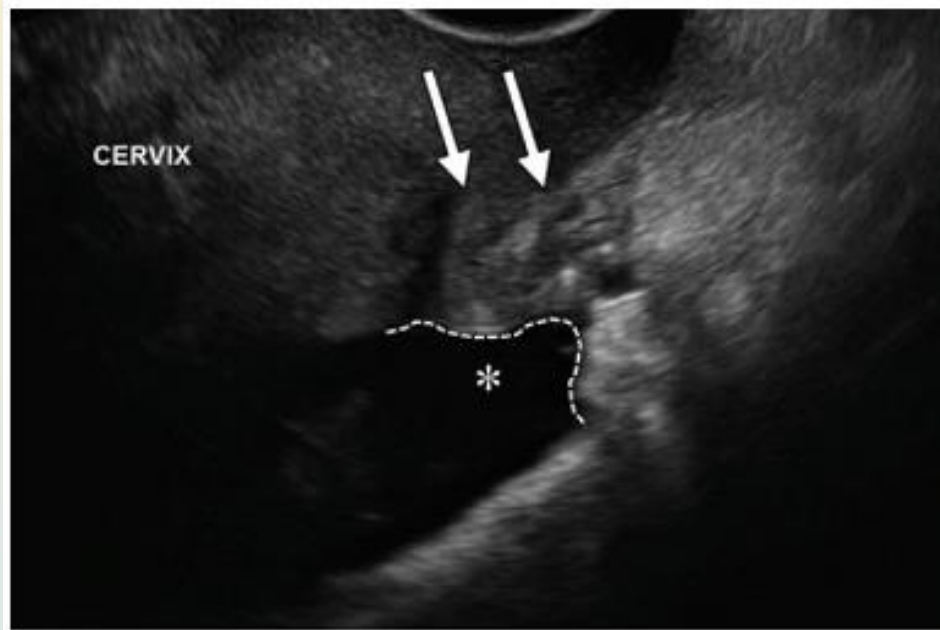
Retrocervical endometriosis in a 31-year-old woman with infertility. Sagittal and coronal T2-weighted MR images show an endometriotic lesion (area inside the dashed line) containing multiple tiny cystic foci. The lesion has infiltrated the posterior uterine serosa and myometrium and is causing uterine retractile retroflexion. Laparoscopic view shows the endometriotic lesion (dashed oval) with associated rectal wall retraction

- ▶ Rectovaginal lesions are frequently extensions from retrocervical or posterior vaginal lesions. They occur as firm nodules that can be palpated at vaginal examination.
- ▶ The purplish nodular infiltrations are easily seen through the speculum, usually in the posterior vaginal wall, where they may cause retraction.
- ▶ At imaging, they have a **hypoechoic appearance** at transvaginal US. The laparoscopic appearance of these endometriotic lesions is similar to that of lesions in the bladder, which are also sub peritoneal and therefore not readily accessible for endoscopic viewing.
- ▶ Careful instrumental palpation of the compromised area with incision of the posterior cul-de-sac peritoneum exposes the lesions.

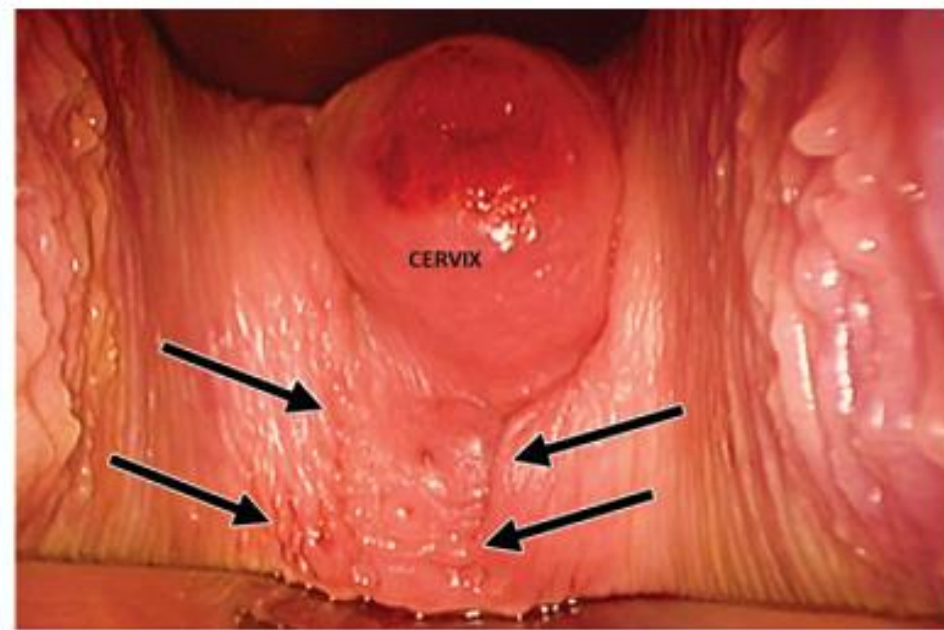
ENDOMETRIOSIS OF THE RECTOVAGINAL SPACE

- ▶ sensitivity of 59.8% _72.1%, with a better rate reported for RCW-TVS (97.1%) followed by SCSV (84.5%) and TG-TVS (74%) and a worse rate in TVS sliding sign
- ▶ specificity had an overall value of 87.5% in a fixed-effects model and 92.4% in a random-effects model with a better rate reported for both RCW-TVS (99.3%) and TG-TVS (98.9%), followed by the remaining procedures, all demonstrating a value greater than 80% ranging from 83.3% of TVS sliding sign to 89.6% of SCSV

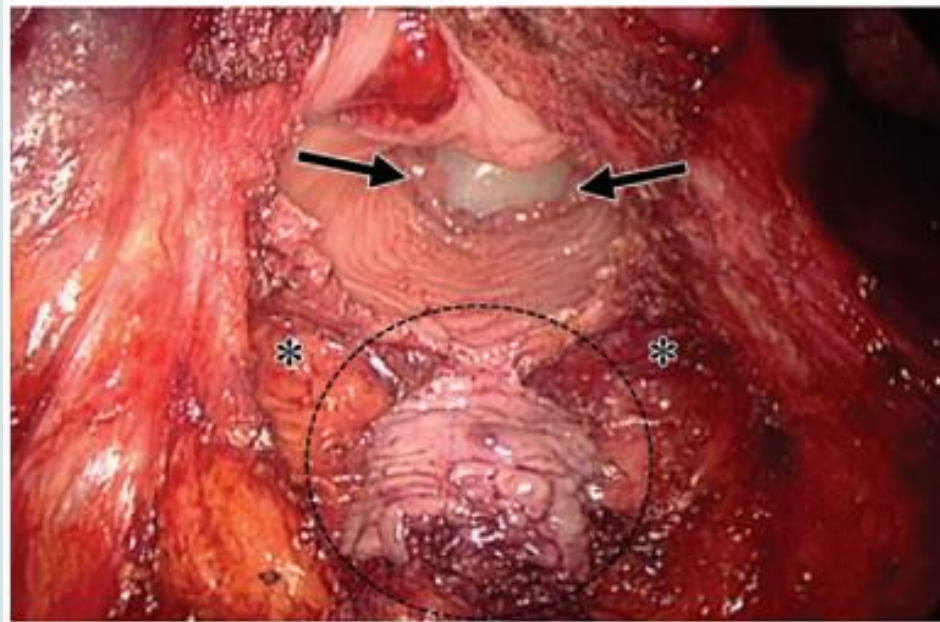
RVS DIE



a.



b.



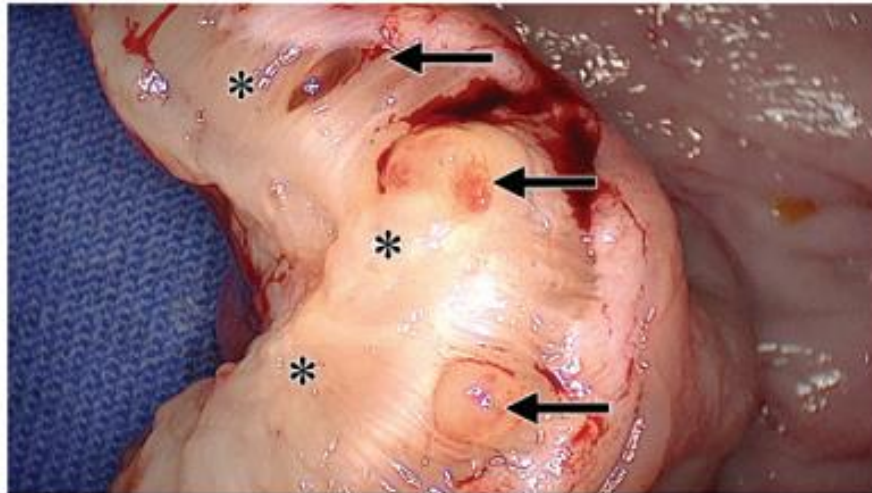
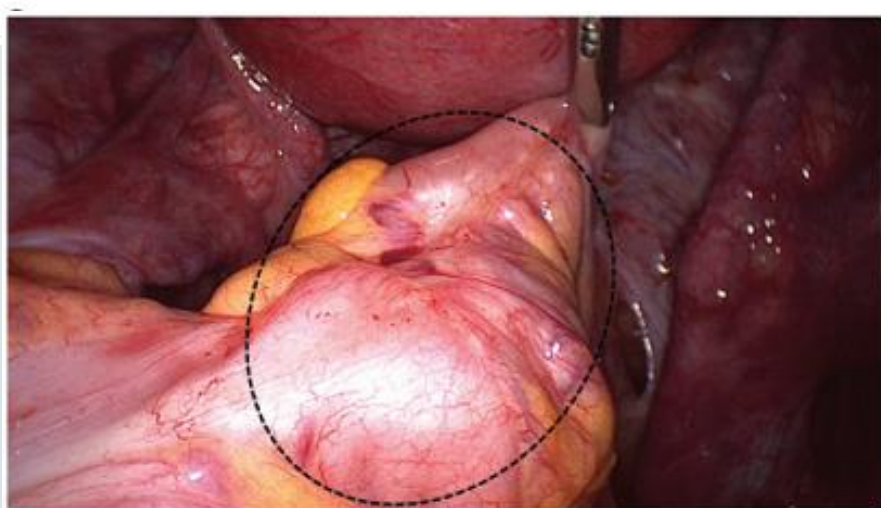
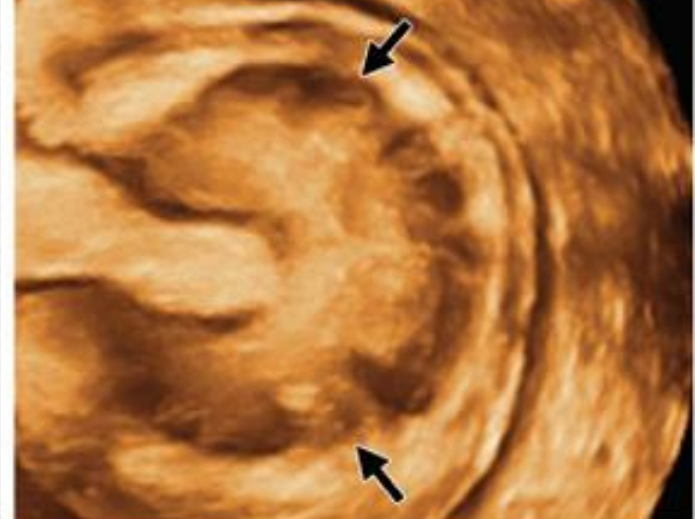
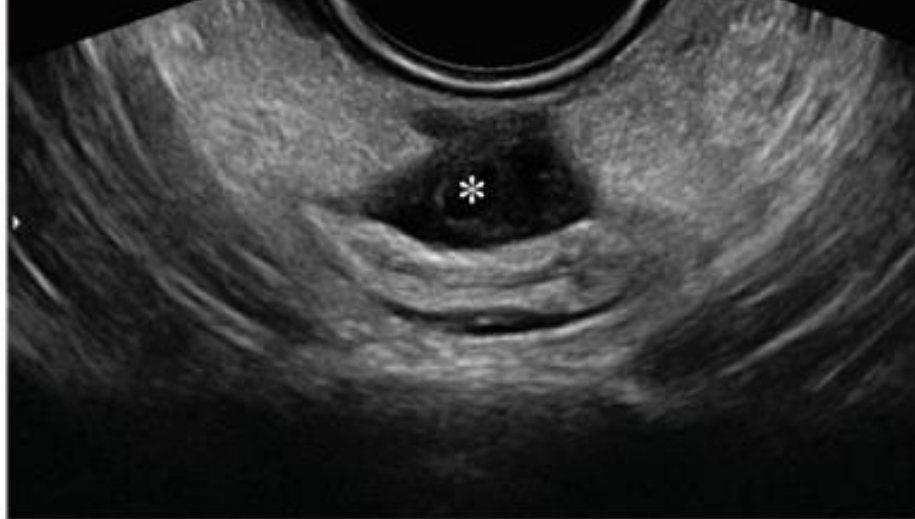
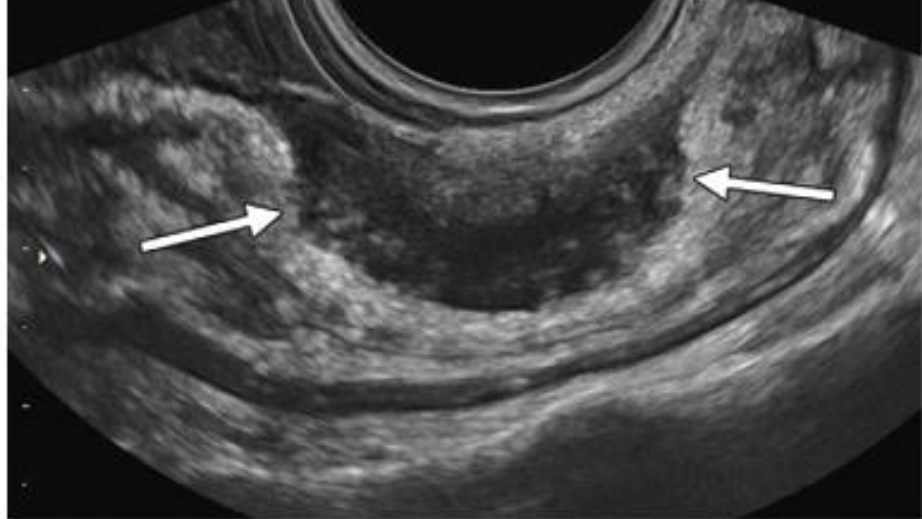
c.

Figure 13. Rectovaginal deeply infiltrating endometriosis in a 28-year-old woman with dyspareunia. **(a)** Sagittal transvaginal US image shows a heterogeneously hypoechoic lesion with small cystic foci just inferior to the peritoneal reflection (dashed line) that has infiltrated the posterior vaginal wall (arrows). A small amount of fluid delimits the Douglas pouch (*). **(b)** Image obtained at vaginal examination demonstrates endometriotic infiltration of the posterior vaginal fornix (arrows). The hemorrhagic region surrounding the external os represents cervical erosion unrelated to endometriosis. **(c)** Laparoscopic view obtained after dissection of the endometriotic lesion (dashed oval) shows the rectovaginal space (*) and hymenal caruncles (arrows).

- ▶ An accurate preoperative diagnosis of bowel endometriosis helps surgeons better prepare for bowel resection and other appropriate treatment.
- ▶ Depending on the lesion size, degree of infiltration, and affected bowel circumference, surgeons may to perform alternative procedures such as shaving or discoid or segmental resection
- ▶ The typical imaging appearance of intestinal endometriotic lesions is a solid, homogeneous nodule with irregular contours attached to the intestinal wall.
- ▶ The differential diagnosis of intestinal lesions is not challenging, because unlike colon cancer
- ▶ deeply infiltrating endometriosis starts at the serosal layer and rarely affects the mucosa.
- ▶ Metastatic implants to the bowel, especially to the small intestinal loops, are another differential diagnosis.

ENDOMETRIOSIS OF THE RECTOSIGMOID COLON

- ▶ They typically display a pyramidal shape, with the base of the pyramid adhering to the anterior rectal wall and the apex oriented toward the retrocervical region. The lesions are usually confined to the serosa or muscularis propria. If a lesion involves the submucosal layer, it demonstrates a striated aspect or areas of interruption in the hyperechoic intestinal layer at transvaginal US
- ▶ Sensitivity of 85.2% _87.9% _with a higher rate reported for both TVS with bowel preparation (97%) and RCW-TVS (94.6%) but the lowest rates reported for both SCSV (66.7%) and TG-TVS (69.5%)
- ▶ specificity is 88.9% _94.4% _with the best rate reported for RCW-TVS (99%) followed by SCSV(93.8%) and TVS sliding sign (93.6%). All the remaining techniques showed a rate greater than 85%, with the results ranging from 86% to 90.2%

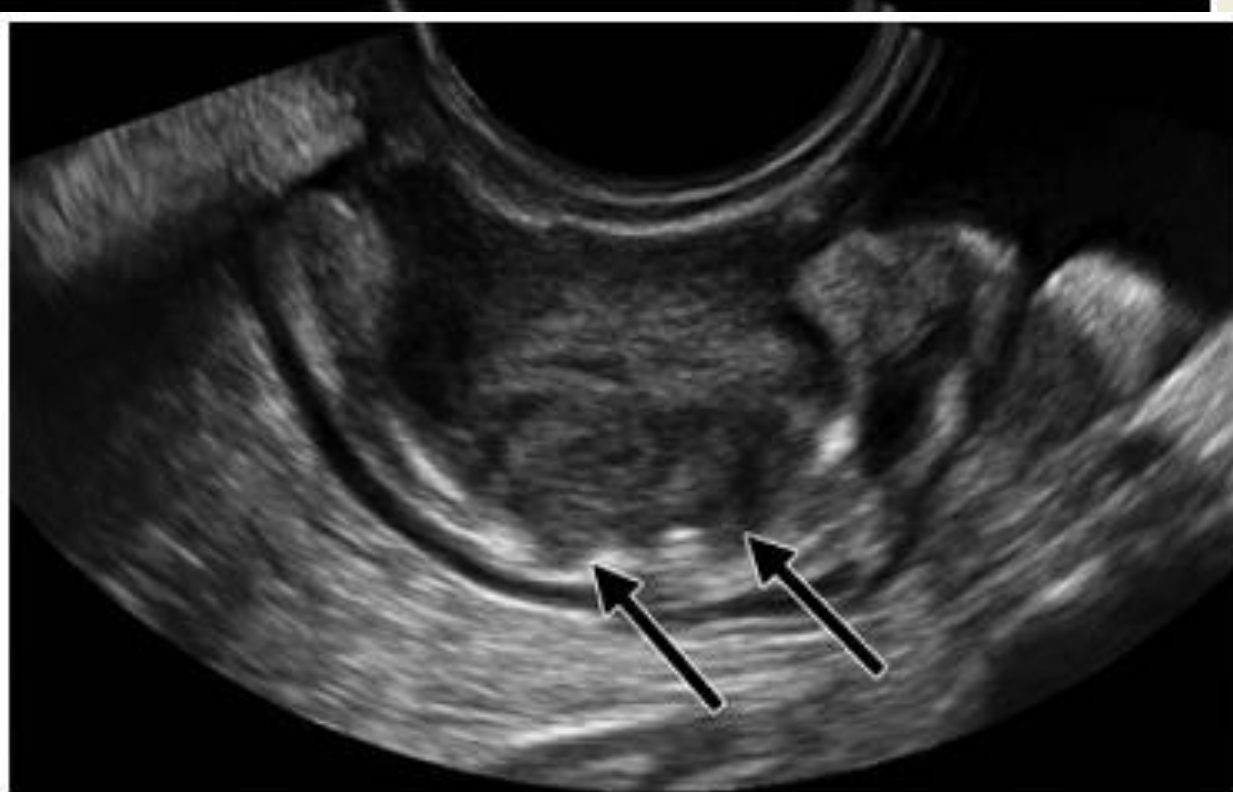

d.

e.

c.

Figure 14. Intestinal endometriosis in a 36-year-old woman. (a)Sagittal transvaginal US image obtained after bowel preparation demonstrates a hypoechoic nodule (arrows) attached to the wall of the sigmoid colon and penetrating the muscularis propria interna. (b)Axial transvaginal US image shows a pyramid-shaped lesion (*) with its base adherent to the anterior rectal wall and its apex pointing toward the retrocervical region. (c)Three-dimensional image from transvaginal US demonstrates retraction of the bowel (arrows) because of fibrotic infiltration. (d)Laparoscopic image depicts a region of bowel wall distortion (dashed oval) with a central depression due to endometriotic infiltration and fibrotic reaction. Only the superficial aspect of the endometriotic lesion is seen. (e)Photograph of a gross specimen of resected bowel shows the endometriotic lesion (*) which contains several small peripheral cysts (arrows)



Intestinal endometriosis in a 40-year-old woman. Sagittal transvaginal US image obtained after bowel preparation shows a hypoechoic nodule attached to the sigmoid colon wall. Hypoechoic areas of discontinuity (arrows) in the normally hyperechoic submucosal layer of the bowel wall are indicative of endometriotic infiltration

mindray

Mother&Child Hosp.
19-01-2016 10:07:01

abasi
20160119-100657-9CD6

V11-3WE / GYN

AP 96.6% MI 1.3 TIS 0.1

DC-8 EXP

B
F 3.2~7.9
D 5.0
G 65
FR 34
DR 125
iClear 3
iBeam 2

-5

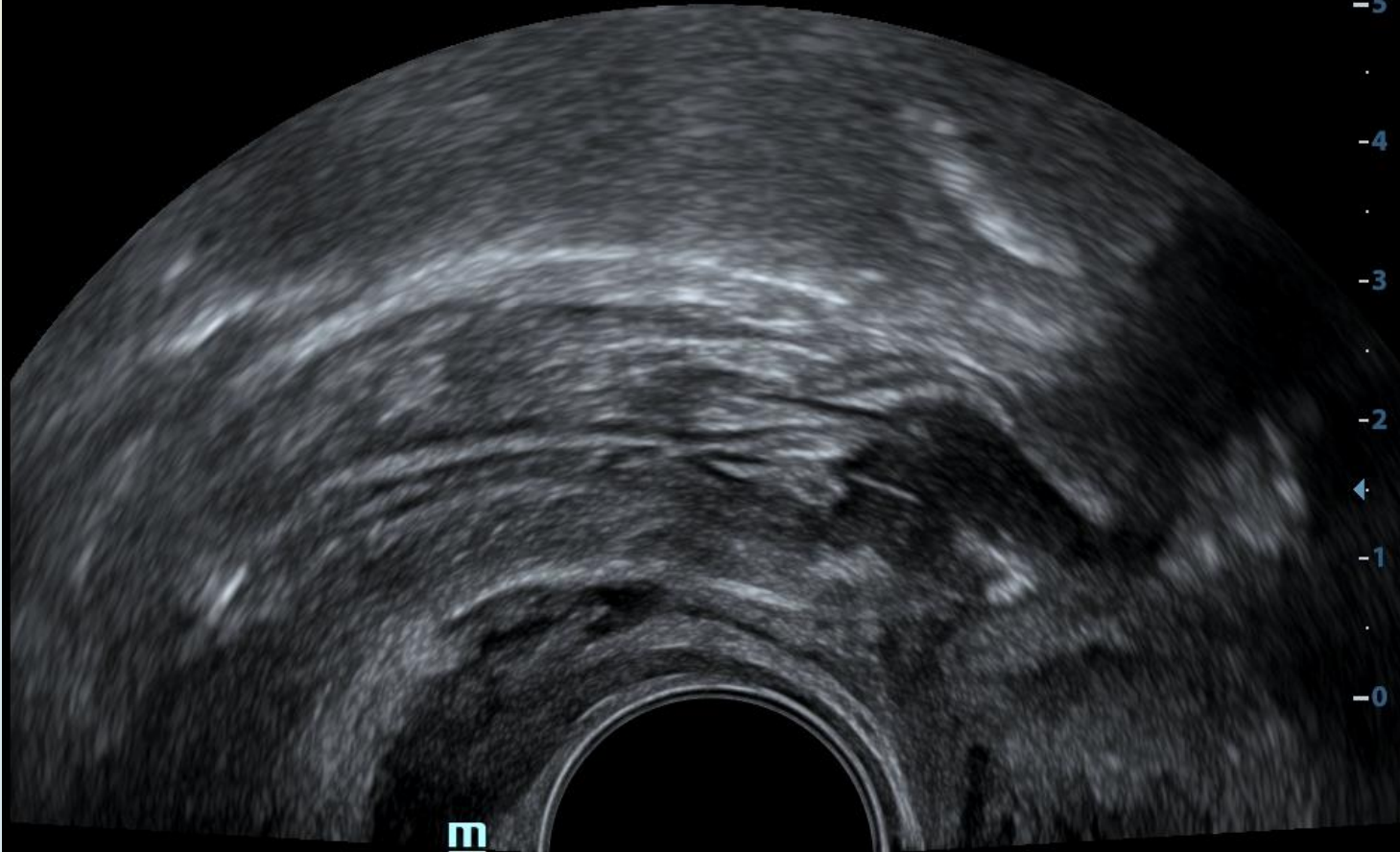
-4

-3

-2

-1

-0

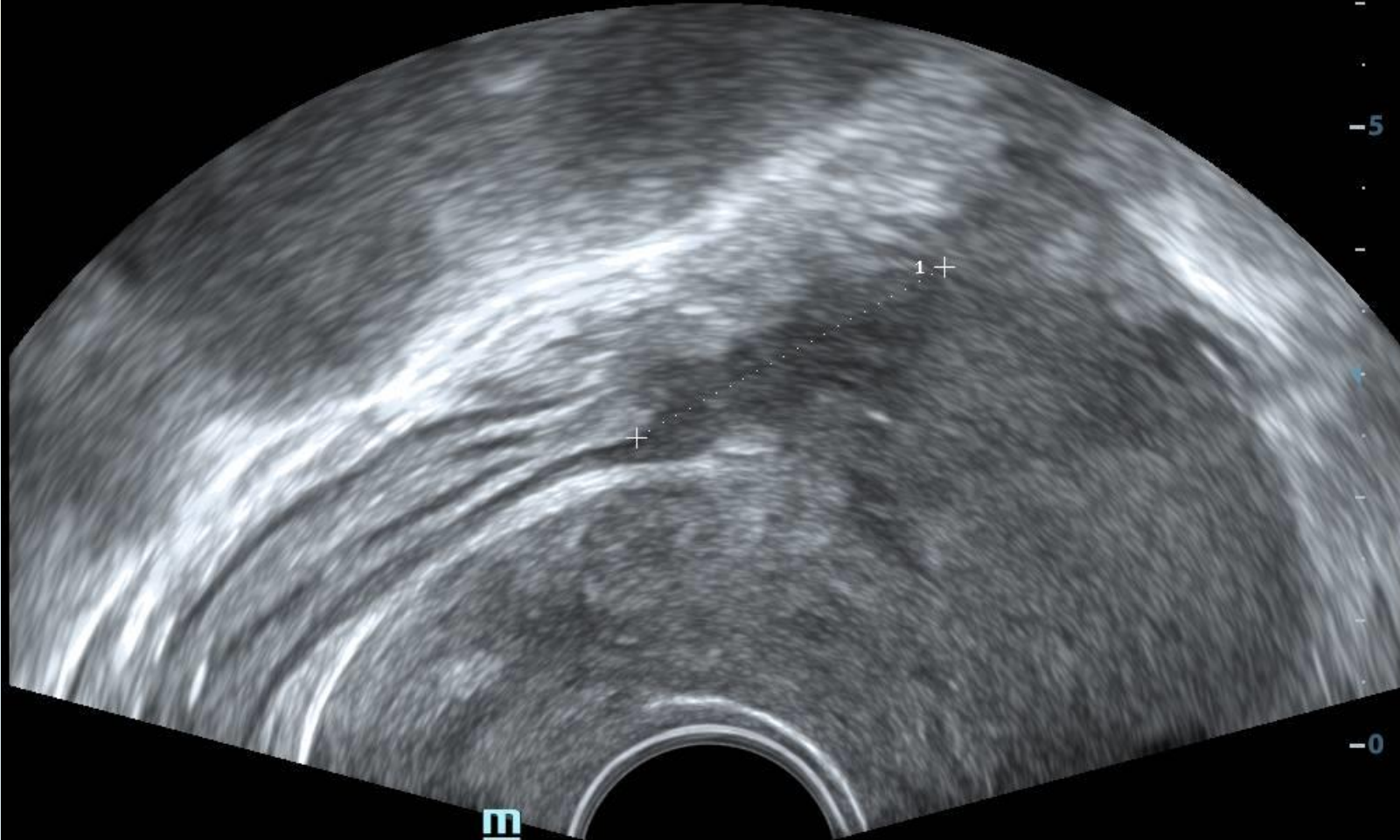

m

AP 96.6% MI 1.3 TIS 0.1

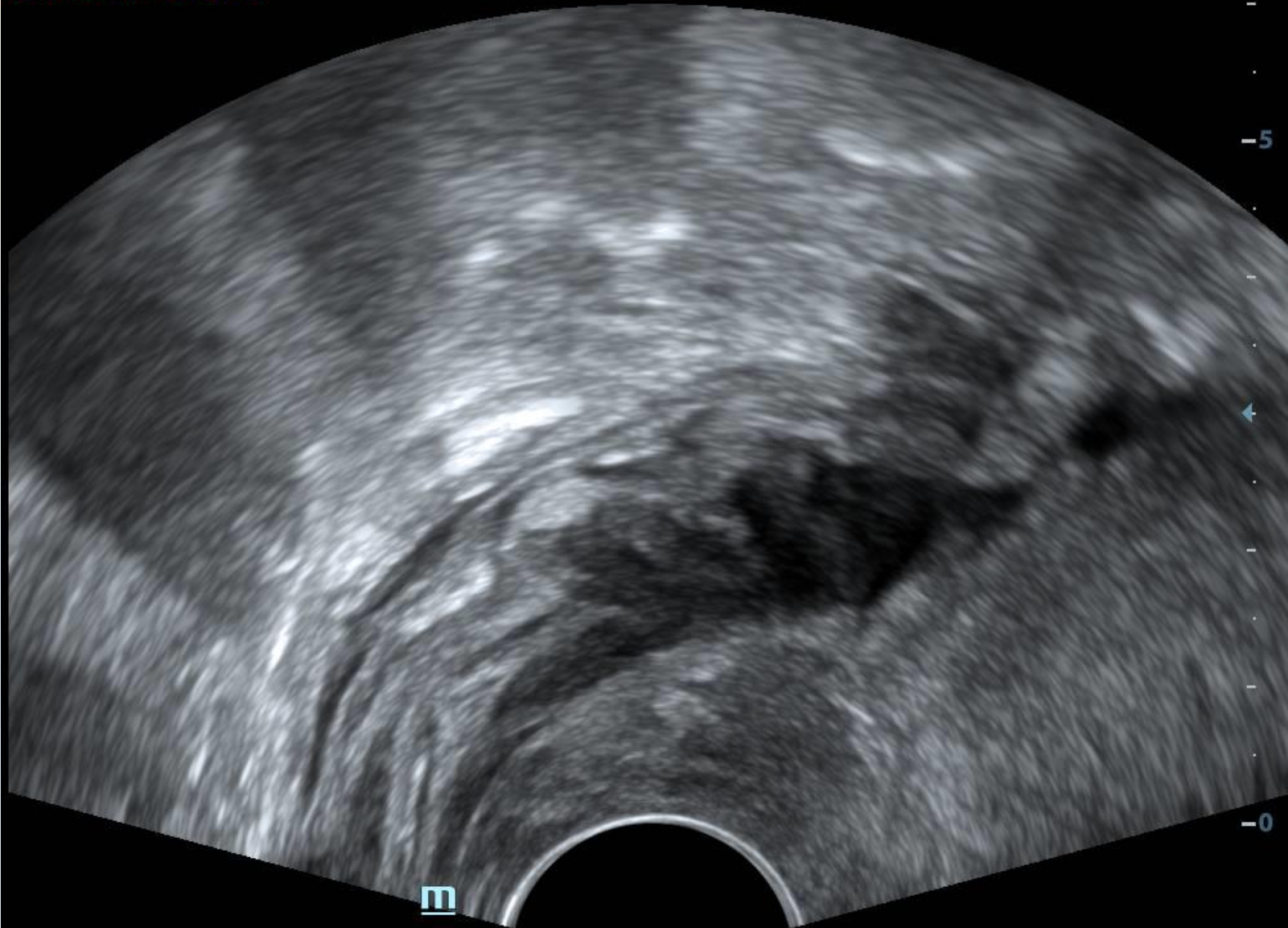
DC-8 EXP

B
F 3.2~7.9
D 6.0
G 59
FR 29
DR 120
iClear 3
iBeam 1



1 Dist 28.5 mm

AP 96.6% MI 1.3 TIS 0.1



DC-8 EXP

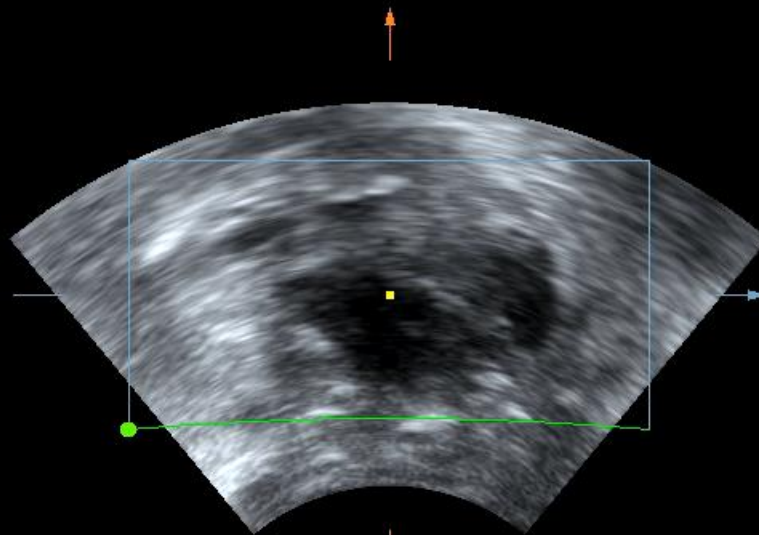
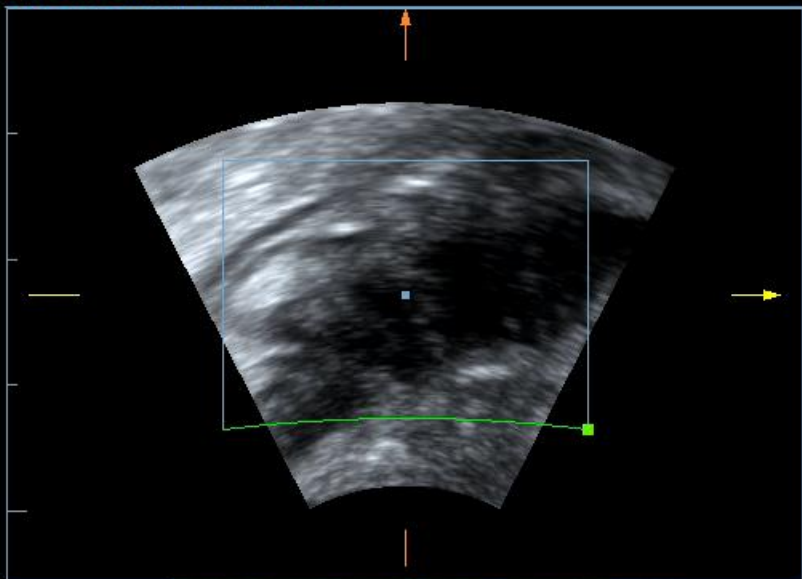
B
F 3.2~7.9
D 6.0
G 59
FR 29
DR 120
Z 1.20
iClear 3
iBeam 1

-5

-0

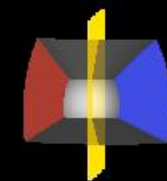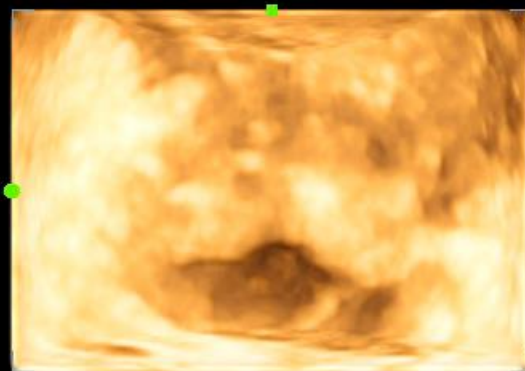
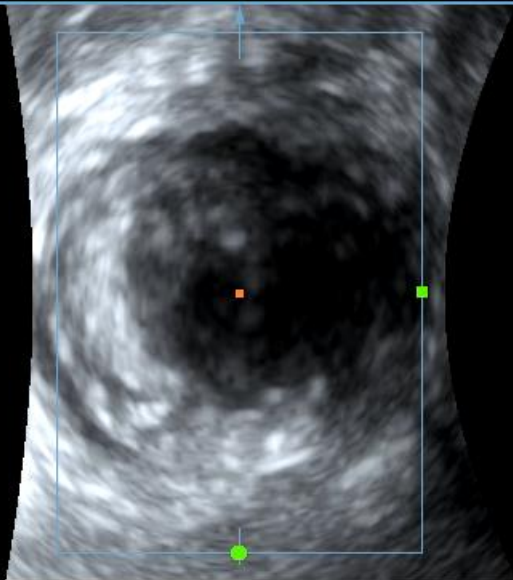
m

AP 96.6% MI 1.1 TIS 0.2



DC-8 EXP

4D
Q high1
A 80°
G 59
T 35%
S 8
C 50%
B 60%
O 70%
VPS 1.9
Surface



▶ 4D movie of rectal DIE

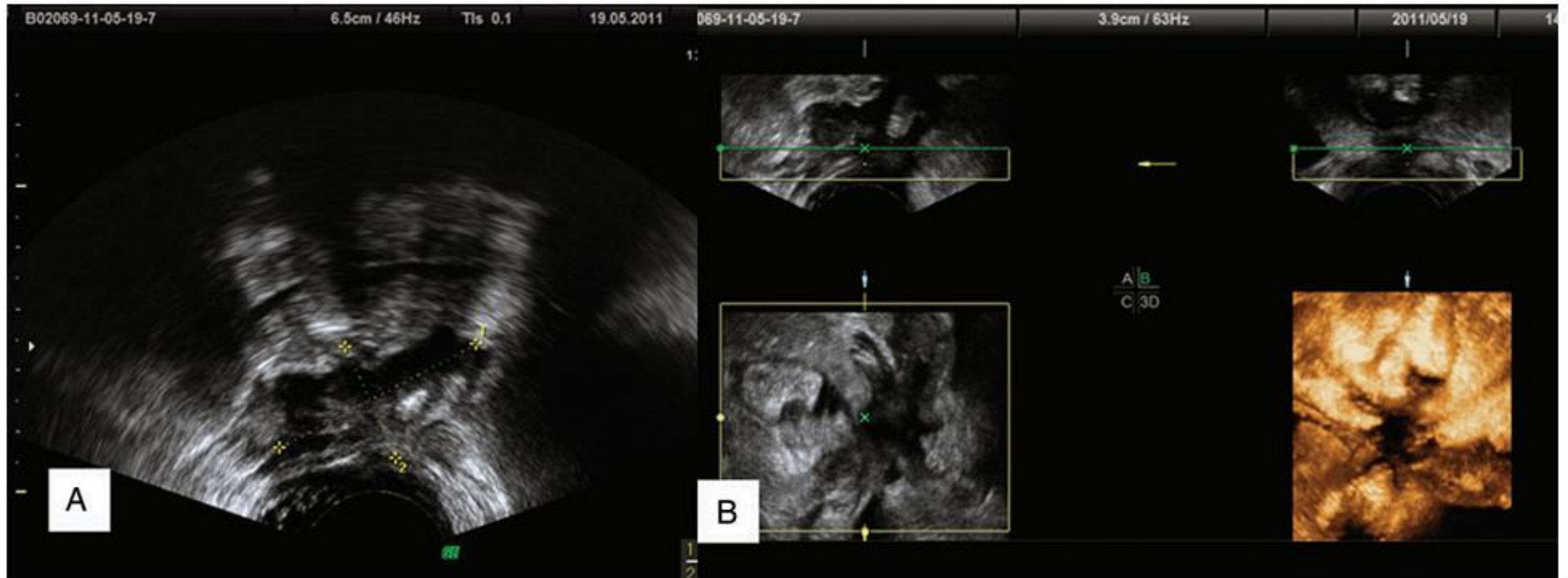
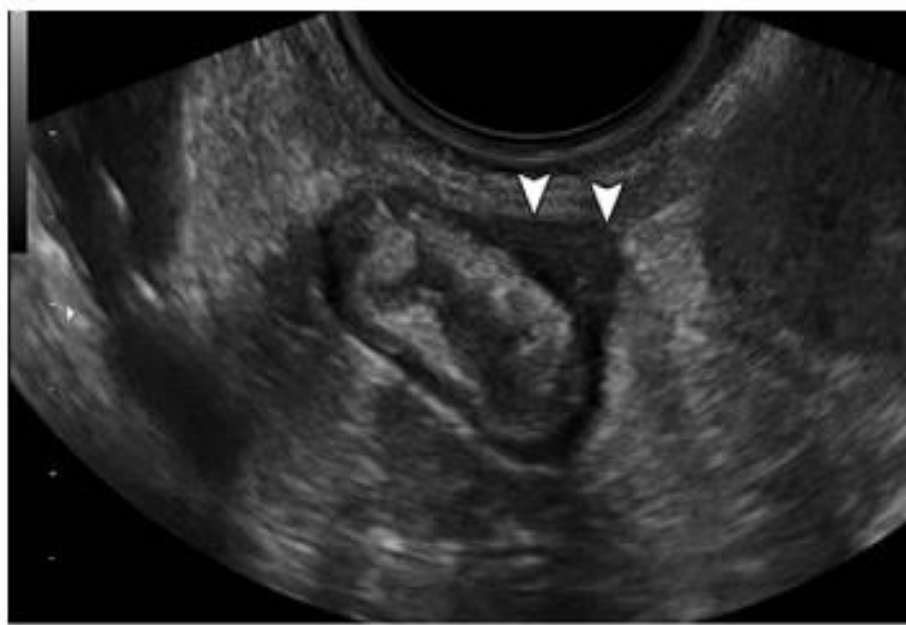
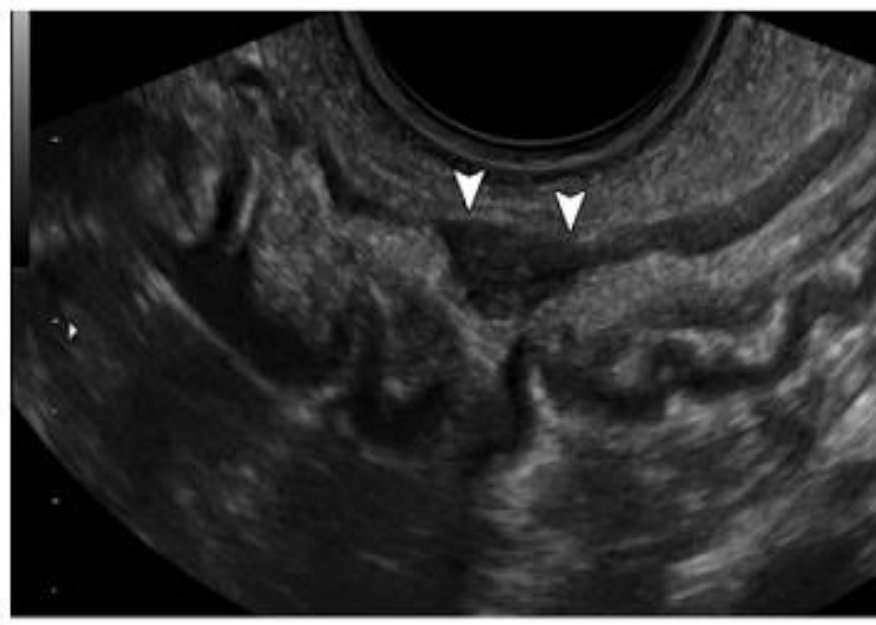
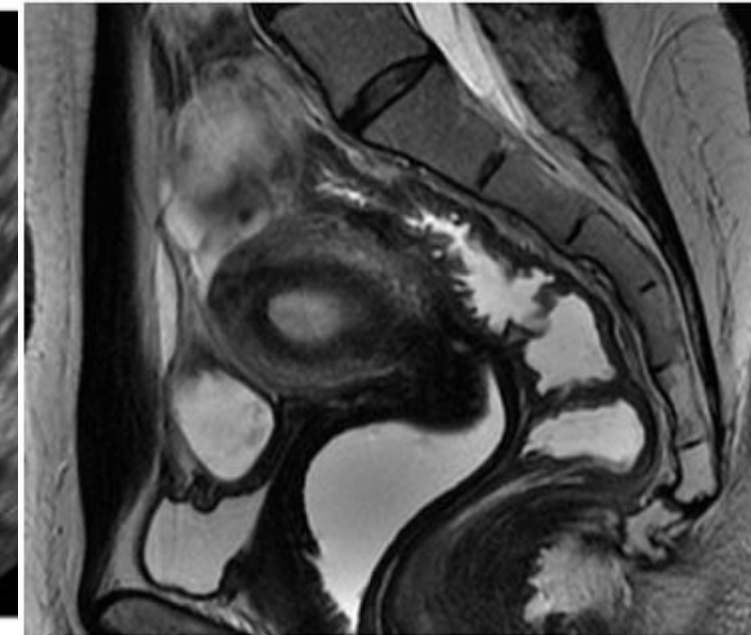
Figure 1 Rectosigmoid lesion as visualized using 2D (**A**) and 3D (**B**) ultrasound in the same patient. The 3D coronal rendering of rectosigmoid lesions showed typically spiculated lesions with retracting lines all around the nodule.



a.



b.

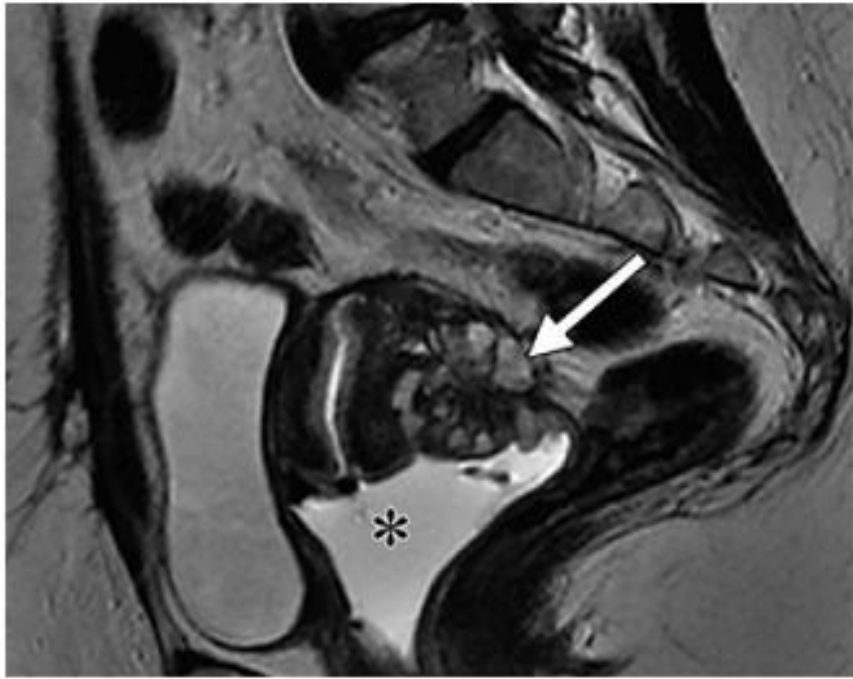


c.

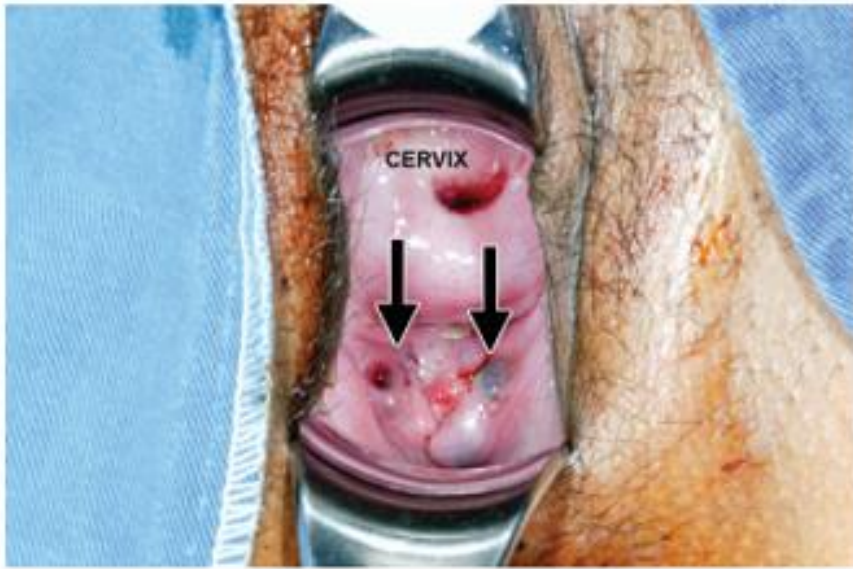
Intestinal endometriosis in a 30-year-old asymptomatic woman. (a, b) Axial (a) and sagittal (b) transvaginal US images obtained after bowel preparation show a small (1.2-cm-diameter) hypoechoic nodule (arrowheads) attached to the wall of the sigmoid colon. (c) Sagittal T2-weighted MR image shows an apparently normal intestinal wall.

- ▶ The condition is almost always associated with endometriosis in other pelvic locations.
- ▶ Insertion of vaginal gel before transvaginal US or MR imaging is useful for visualizing the posterior fornix and the interface between the posterior cervical lip and vaginal wall .
- ▶ Vaginal **endometriotic nodules are hypoechoic on transvaginal US images** and demonstrate low signal intensity on T2-weighted MR images. They generally have **a mixed internal appearance due to the presence of cystic areas.**
- ▶ sensitivity of 46.9% _65.1% with a better rate reported for SCSV (94.7%) and a worse rate for RES (12.3%). The remaining techniques showed a rate ranging from 49.5% to 91%
- ▶ the specificity, of 92.3% _93.8% with a better rate reported for RES (97.3%), despite also the lowest value reported for TVS (88.4%), were acceptable results

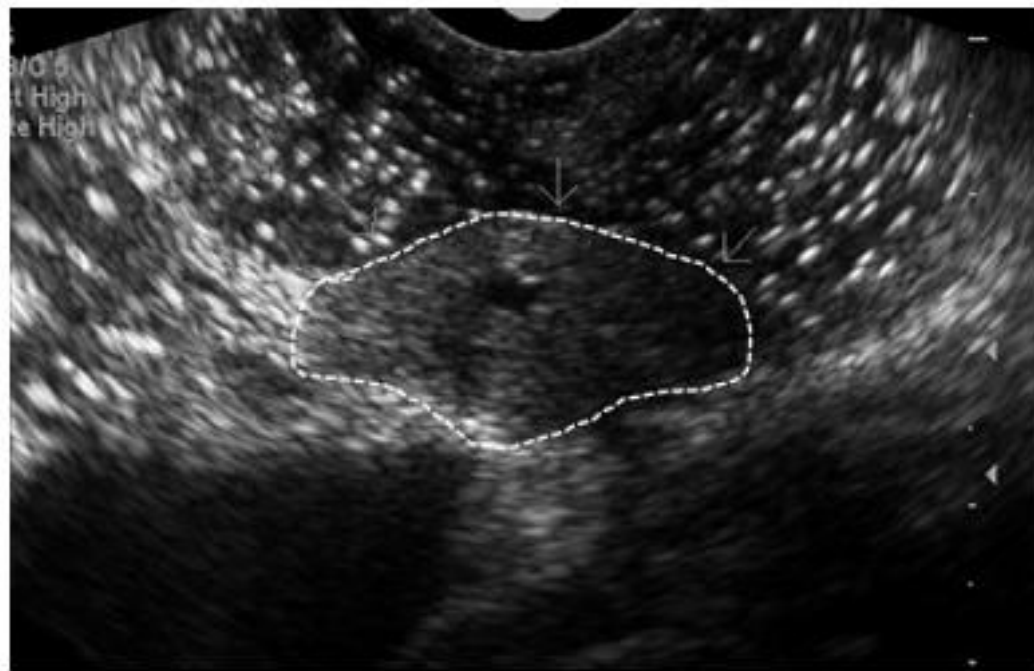
VAGINAL ENDOMETRIOSIS



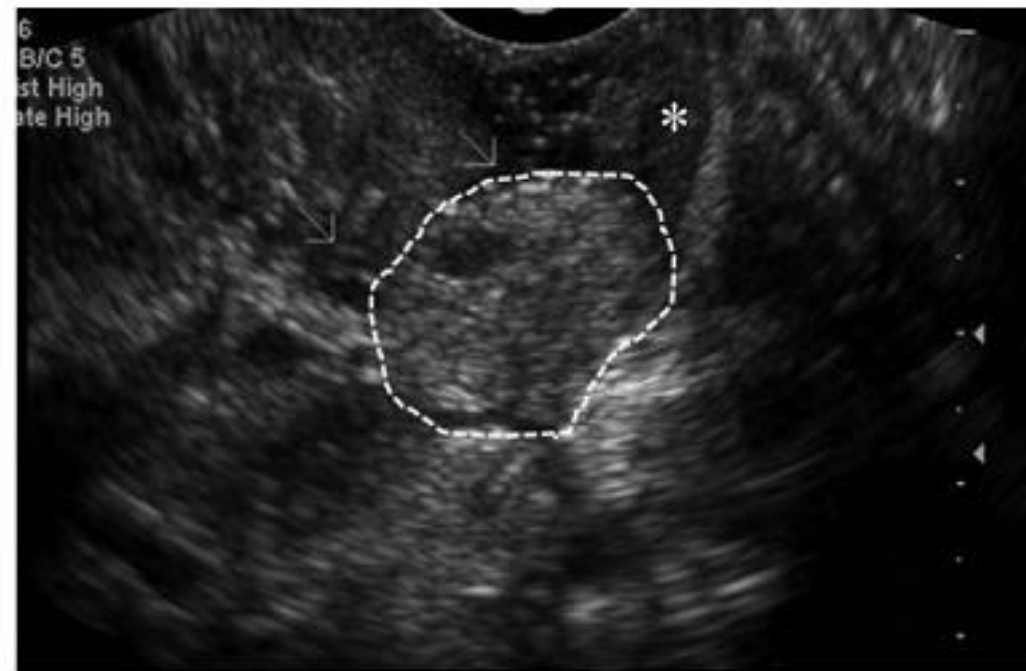a.



Vaginal endometriosis in a 37-year-old woman with pelvic pain and dyspareunia. (a) Sagittal T2-weighted MR image shows a large mixed (solid and cystic) endometriotic lesion (arrow) in the retro-cervical region and posterior vaginal fornix. Distention of the vagina with gel (*) facilitates identification of the lesion. (b) Image from a vaginal examination shows that the endometriotic lesion occupies the posterior vaginal fornix (arrows).



a.



b.

Figure 21. Vaginal endometriosis in a 31-year-old woman with dyspareunia. **(a)** Transverse transvaginal US image shows a nodule (ovoid dashed line) that contains a small cystic area. The nodule is attached to the posterior vaginal wall and protrudes into the posterior fornix. The gel used for vaginal distention produces multiple hyperechoic foci, facilitating visualization of the nodule. **(b)** Sagittal transvaginal US image depicts the same nodule (ovoid dashed line). Normal vaginal wall (*) is seen inferior to the lesion.

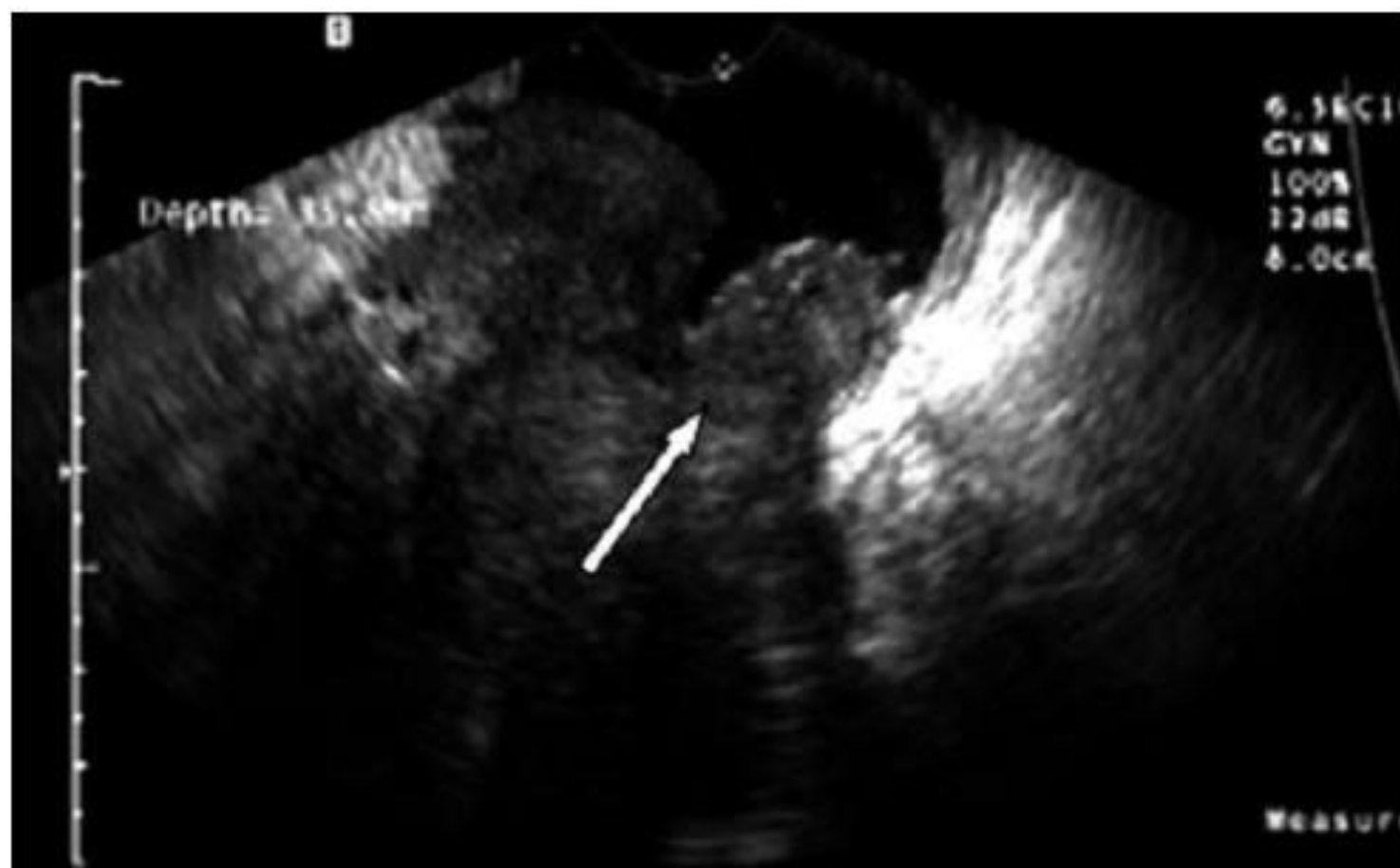

Figure 1 Saline contrast sonovaginographic image showing exophytic endometriotic lesion (arrow) at level of posterior vaginal fornix.

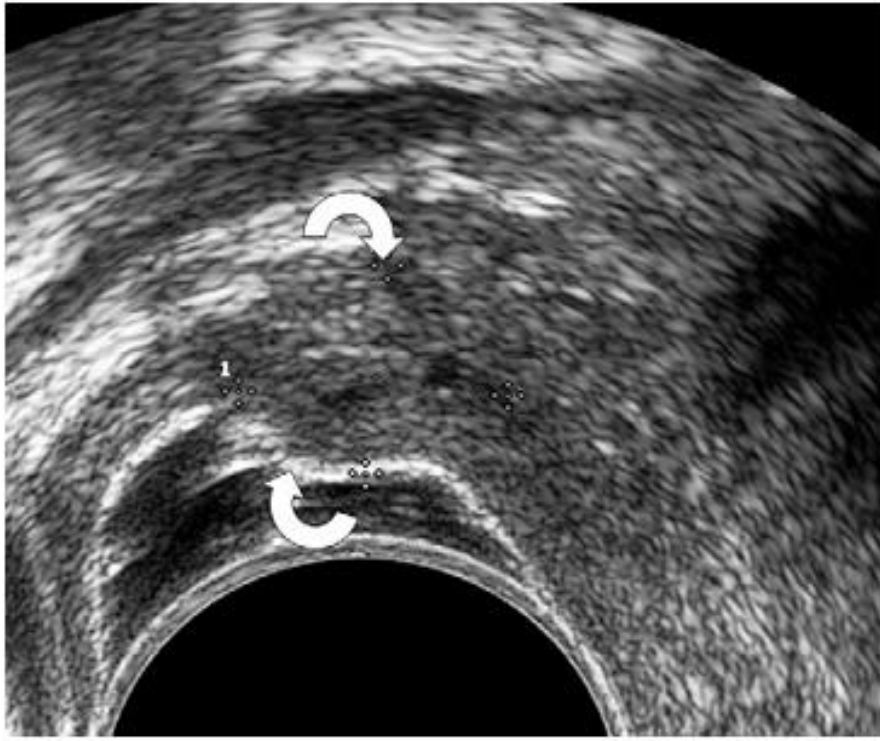

Figure 2: An endometriotic nodule (curved arrow) in the vaginal wall.

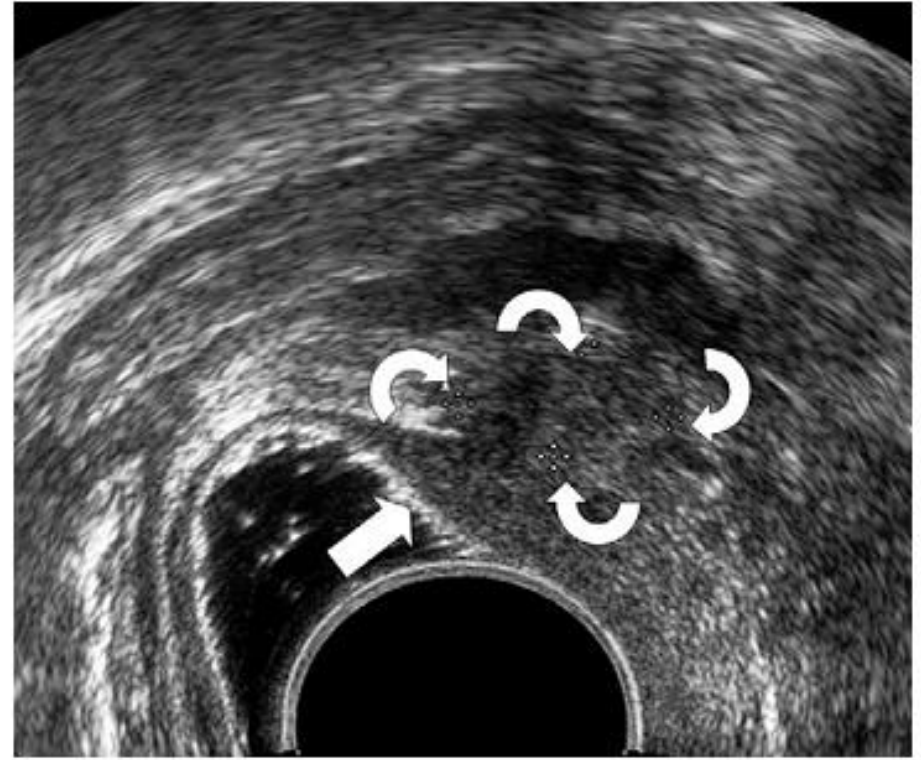

Figure 3: A nodule involving the rectovaginal septum (curved arrows).

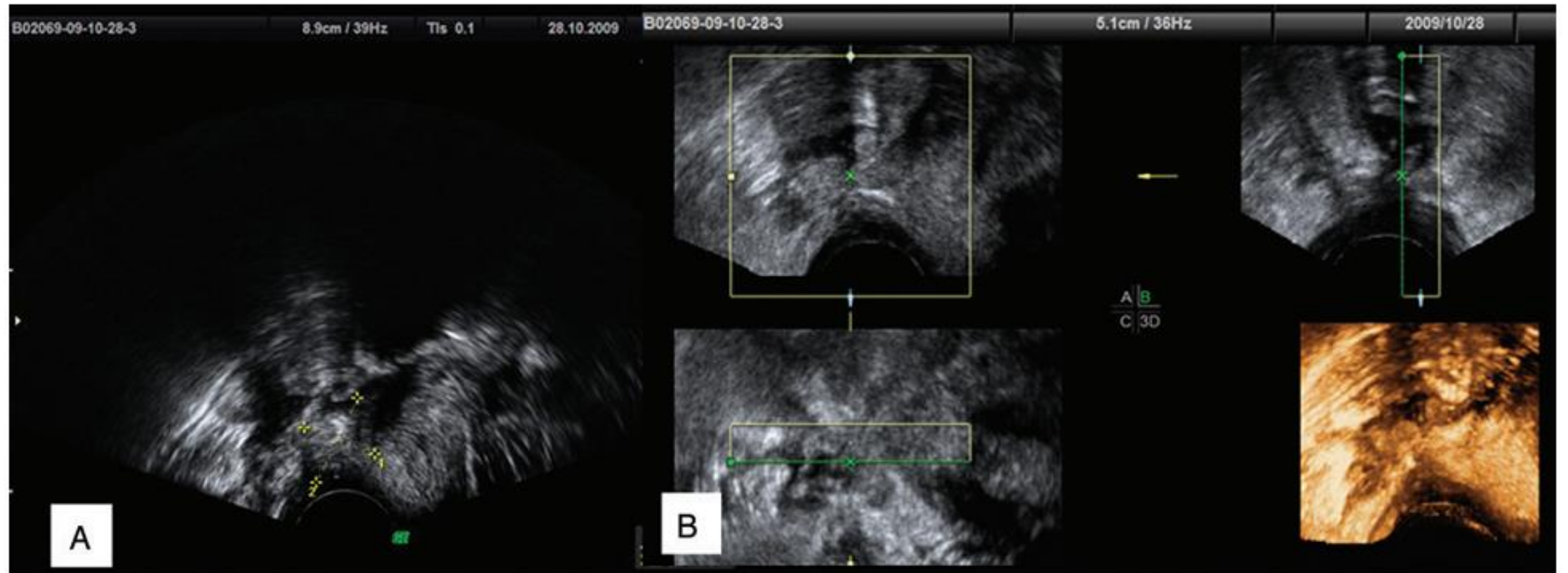
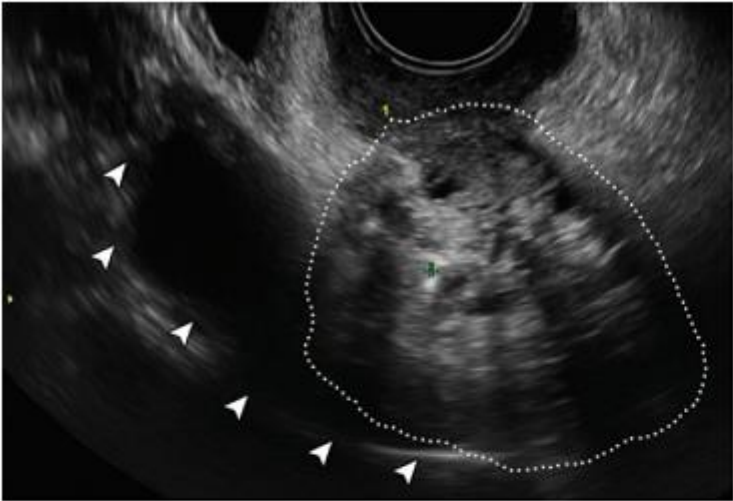


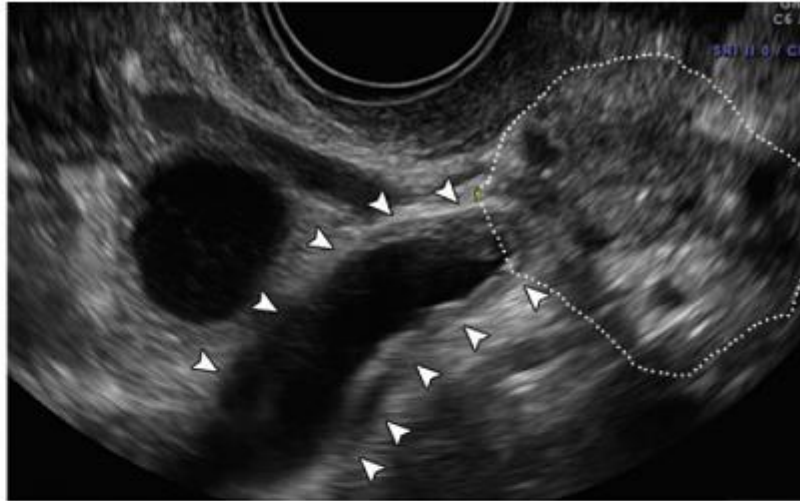
Figure 2 Vaginal forniceal lesion as visualized using 2D (**A**) and 3D (**B**) ultrasound in the same patient with extension toward the anterior rectal muscularis.

- ▶ Preoperative diagnosis is unlikely unless associated ureteral obstruction or hydronephrosis occurs.
- ▶ It is estimated that 47% of patients with ureteral endometriosis require nephrectomy at the time of diagnosis..
- ▶ The possibility of ureteral involvement must be considered in the presence of large paracervical lesions (≥ 2 cm in diameter).
- ▶ Renal US may depict hydronephrosis, but unless the ureters are dilated, it is difficult to visualize the ureteral. Ingestion of approximately 300 mL of water just before transvaginal US allows identification of the ureter and its peristaltic movement from the segment below the iliac vessels to the ureterovesical junction. Color or power Doppler US may demonstrate a jet indicative of unobstructed ureteral flow
- ▶ the best imaging modality for ureteral evaluation is pelvic MR imagingPelvic. MR imaging combined with MR urography allows a complete work-up in a single imaging evaluation
- ▶ The lesions are hypoechoic on transvaginal US images and show low signal intensity on T2-weighted MR images. They may arise from the uterosacral ligament, broad ligaments, ovaries, or any peritoneal tissue along the ureteral pathway. The ureteral segment distal to the obstructive lesion has a normal diameter.

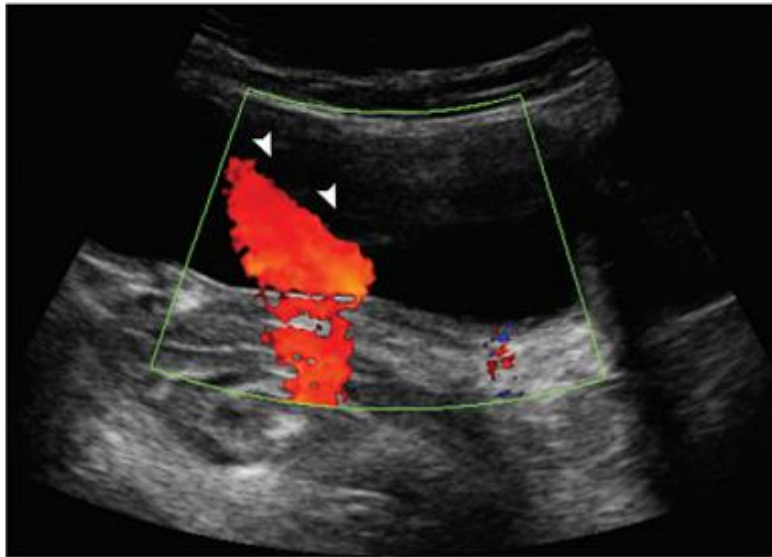
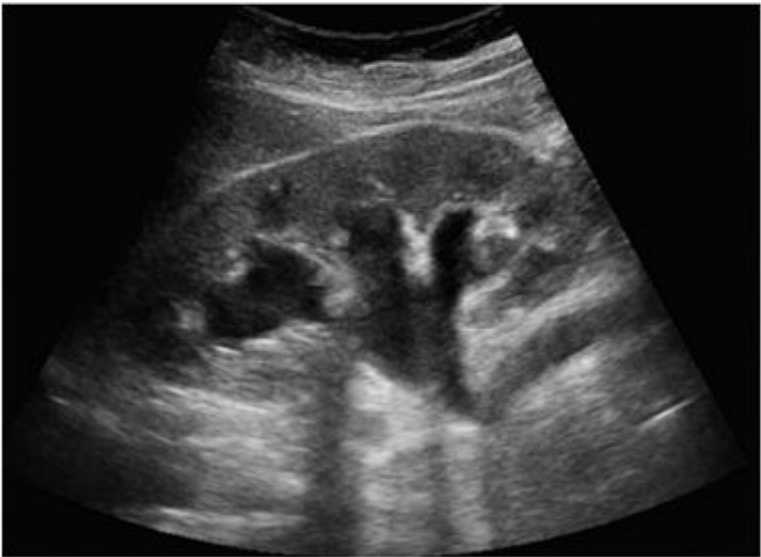URETERAL ENDOMETRIOSIS



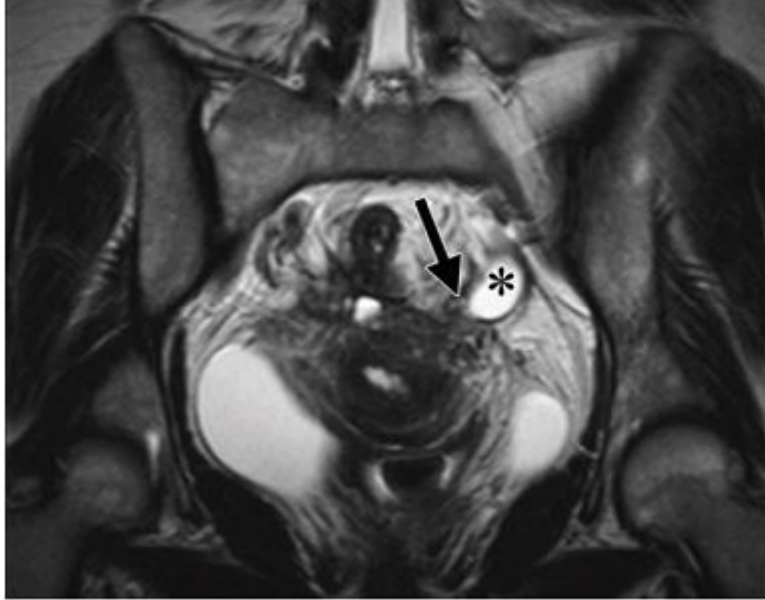
a.



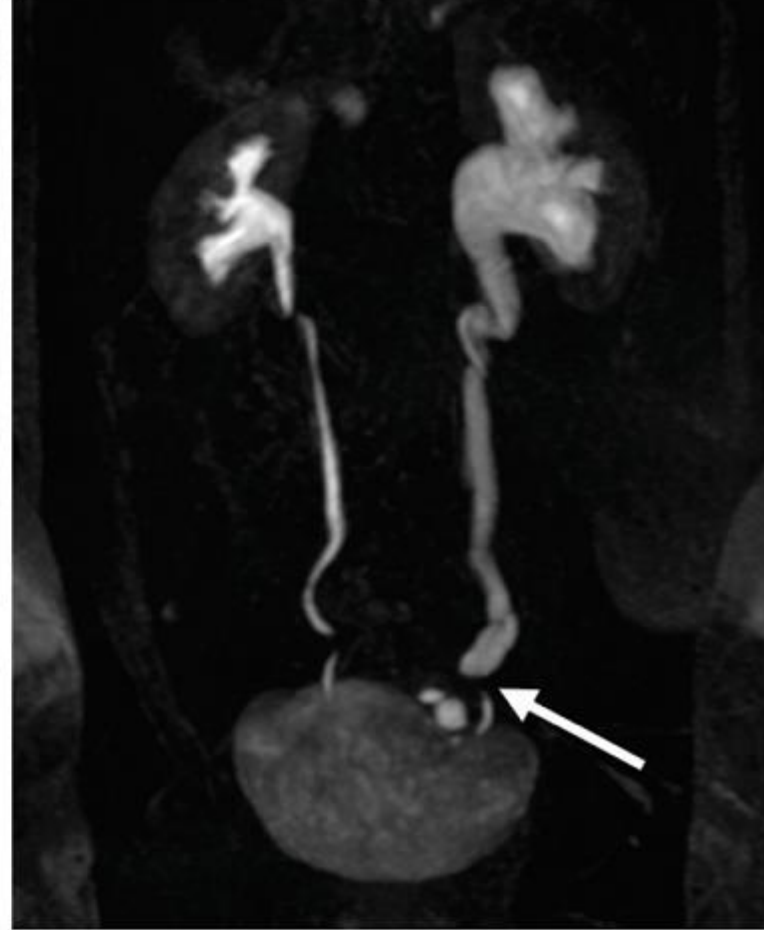
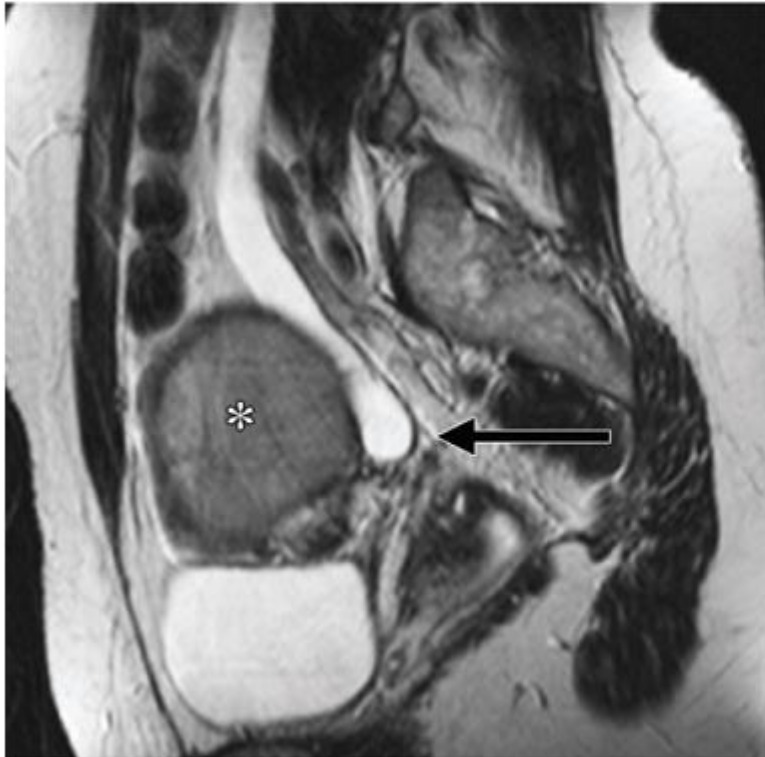b.



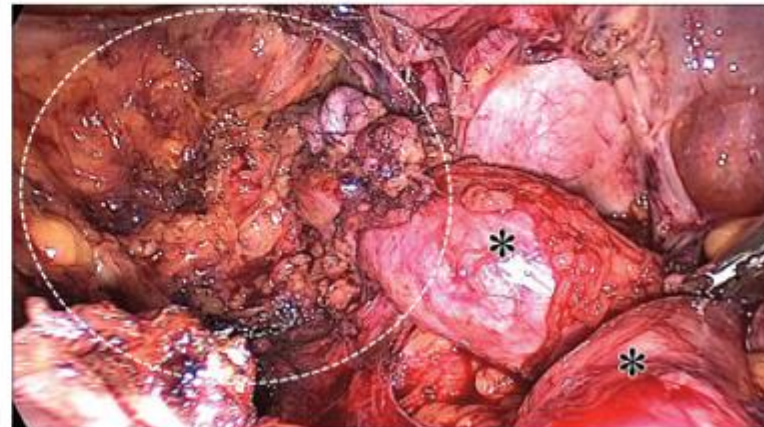
Paracervical endometriosis with ureteral stenosis in a 35-year-old woman with infertility. (a, b) Sagittal oblique transvaginal US images show a large heterogeneous paracervical mass (ovoid dotted line) representative of an endometriotic lesion that has surrounded the dilated left ureter (arrowheads). The lesion is best depicted in a, and the ureteral dilatation, in b. (c) Transabdominal US image of the left kidney demonstrates moderate hydronephrosis. (d) Transabdominal power Doppler US image shows a left ureteral jet (arrowheads).



a.



c.

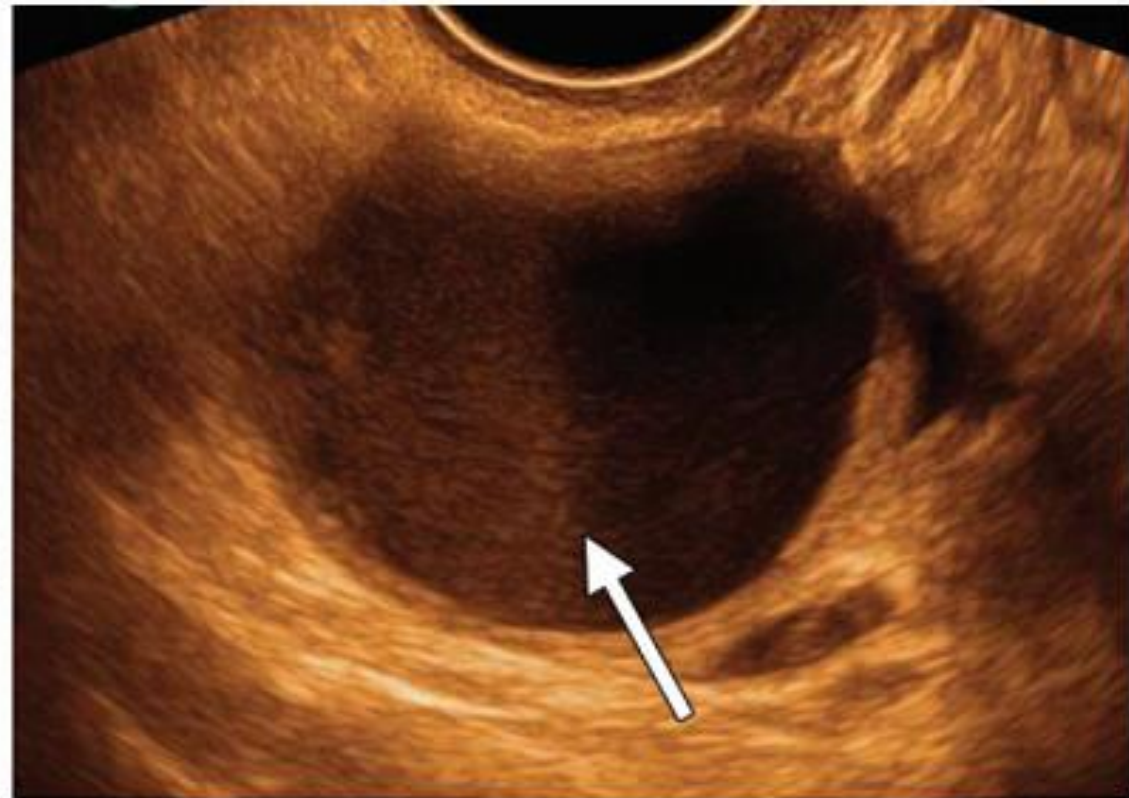
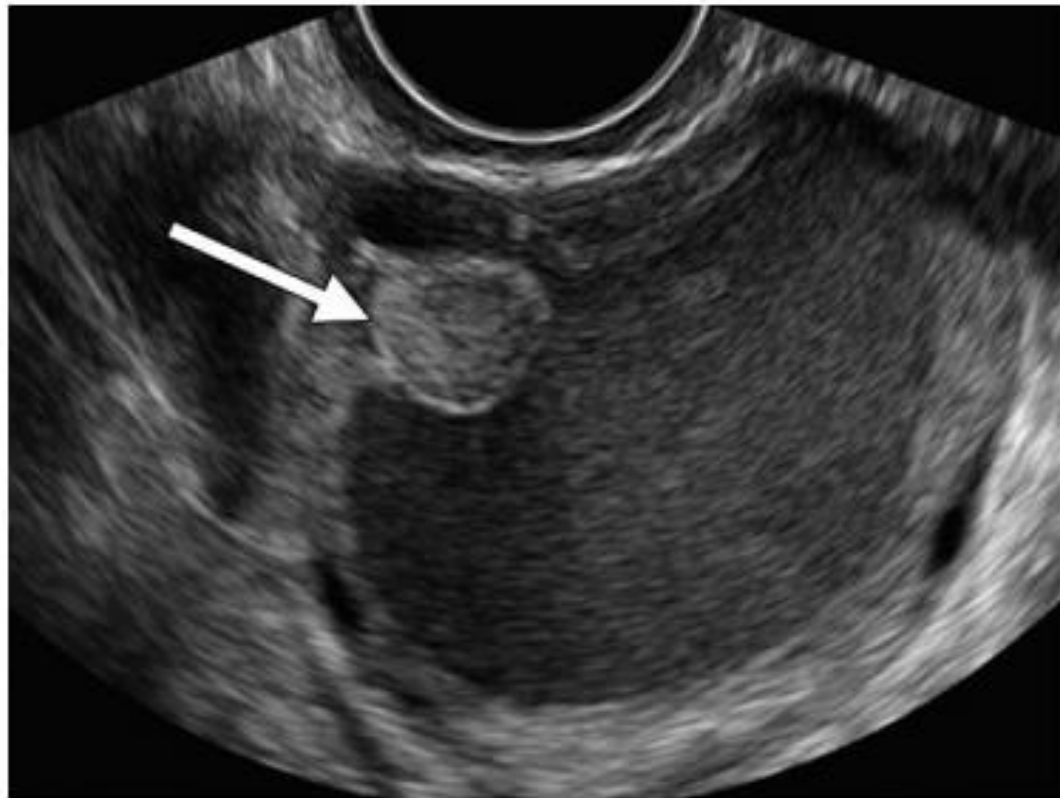


Paracervical endometriosis with ureteral stenosis in a 37-year-old woman with dysmenorrhea and infertility. (a) Coronal T2-weighted MR image demonstrates left paracervical thickening (arrow) that involves the ureter (*). (b) Sagittal T2-weighted MR image shows ureteral stenosis and dilatation near the lesion (arrow). There is also an endometrioma (*) in the left ovary. (c) MR urogram shows an asymmetric appearance of the ureters. The entirety of the left ureter above the point of obstruction (arrow) is dilated, whereas the distal segment has a diameter similar to that of the right ureter. (d) Laparoscopic image shows the endometriotic mass (dashed oval) and the dilated pelvic ureter (*)

- ▶ The ovaries are among the most common sites of endometriosis (20%–40% of cases). Ovarian endometriosis may manifest either as superficial fibrotic implants associated with fibrous adhesions or as chronic retention cysts with cyclic bleeding (endometriomas)
- ▶ Endometriosis confined to the ovarian surface is underdiagnosed at imaging because of the microscopic size of the lesions. Endometriomas are thick-walled cysts with a dark, dense content that represents degenerated blood products .
- ▶ Endometriomas may include peripheral nodules (blood clots) or fluid-fluid levels due to recent hemorrhages
- ▶ Endometriomas are a marker of severity of deeply infiltrating endometriosis . The risks for multifocal disease and intestinal involvement in patients with an endometrioma are two- to threefold the risks among patients with endometriosis but without an endometrioma. These observations highlight the importance of a careful search for severe, deeply infiltrating endometriotic lesions in patients with endometriotic cysts.
- ▶ In the differential diagnosis of endometriomas, transvaginal US is highly sensitive (84%–100%) and specific (90%–100%).

OVARIAN ENDOMETRIOSIS

- ▶ Most endometriomas exhibit homogeneous, diffuse internal hypoechogenicity. Thin or thick septa, fluid-fluid levels, echogenic peripheral nodules, and bright foci within the cysts may be observed
- ▶ On color Doppler US images, the cysts appear hypovascular, without internal flow.
- ▶ Transvaginal US is also useful for preoperative evaluations of adhesions: fixation of at least one ovary to the uterus
- ▶ The differential diagnosis of endometrioma includes hemorrhagic corpus luteum cysts. The latter are usually unilocular, have a “reticulated” pattern on transvaginal US images
- ▶ Dermoid cysts may mimic endometriomas, but they can be differentiated by the presence of a chemical shift artifact and signal dropout on fat-suppressed MR images
- ▶ multiple corpora lutea, which may be seen after induced ovulation. The isolated appearance of each corpus
- ▶ luteum cyst in such cases is similar to that of the functional corpus luteum, but the patient’s medical history includes recent oocyte retrieval.



25.

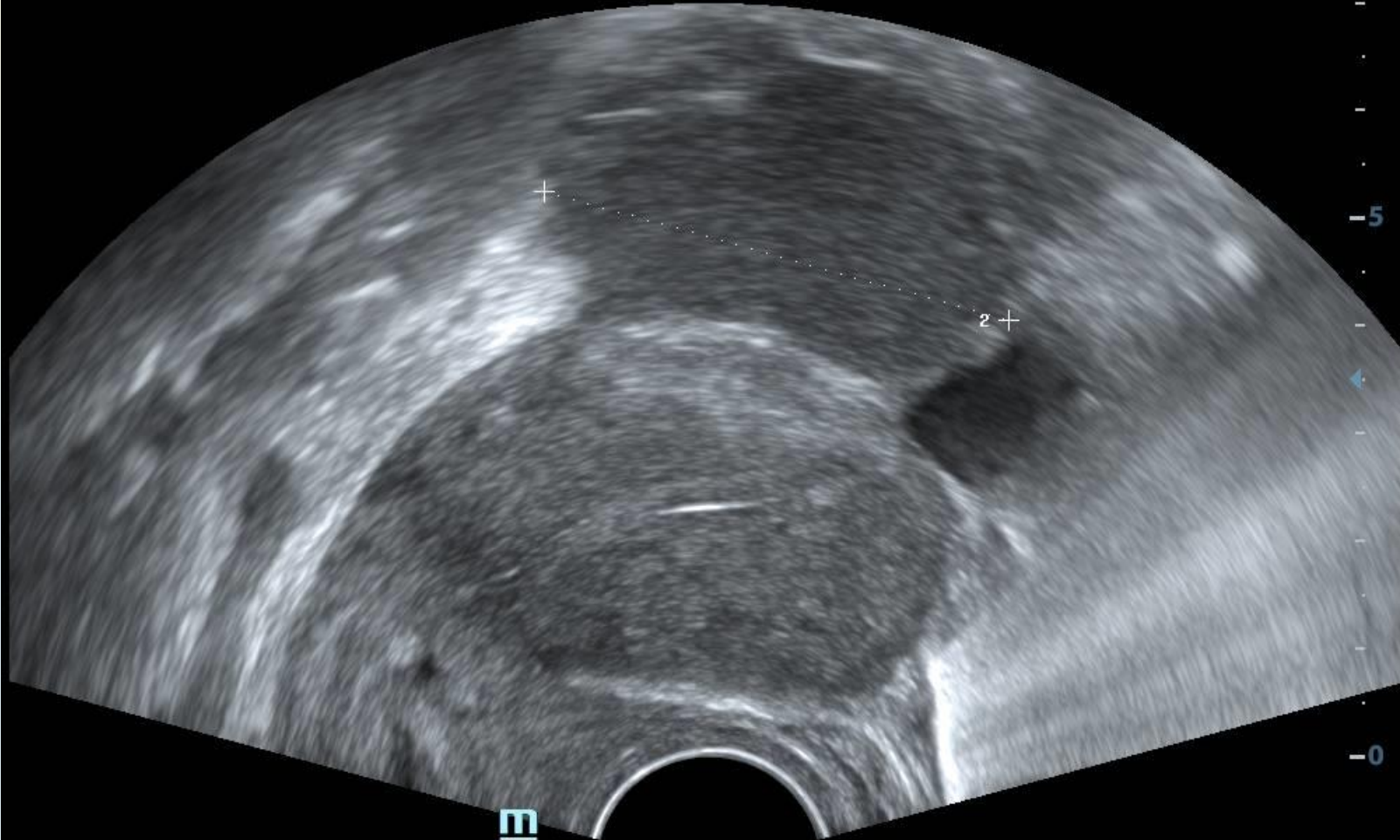26.

Figures 25, 26. Endometriomas. (25) Transvaginal US image obtained in a 26-year-old woman with pelvic pain shows an endometrioma with a hyperechoic peripheral nodule (arrow) in the right ovary. (26) Transvaginal US image obtained in a 28-year-old woman shows an endometrioma with a fluid-fluid level (arrow) in the left ovary. The lighter area to the left of the arrow represents more recent hemorrhage, a finding made more recognizable by the sepia colorization.

AP 96.6% MI 1.3 TIS 0.1

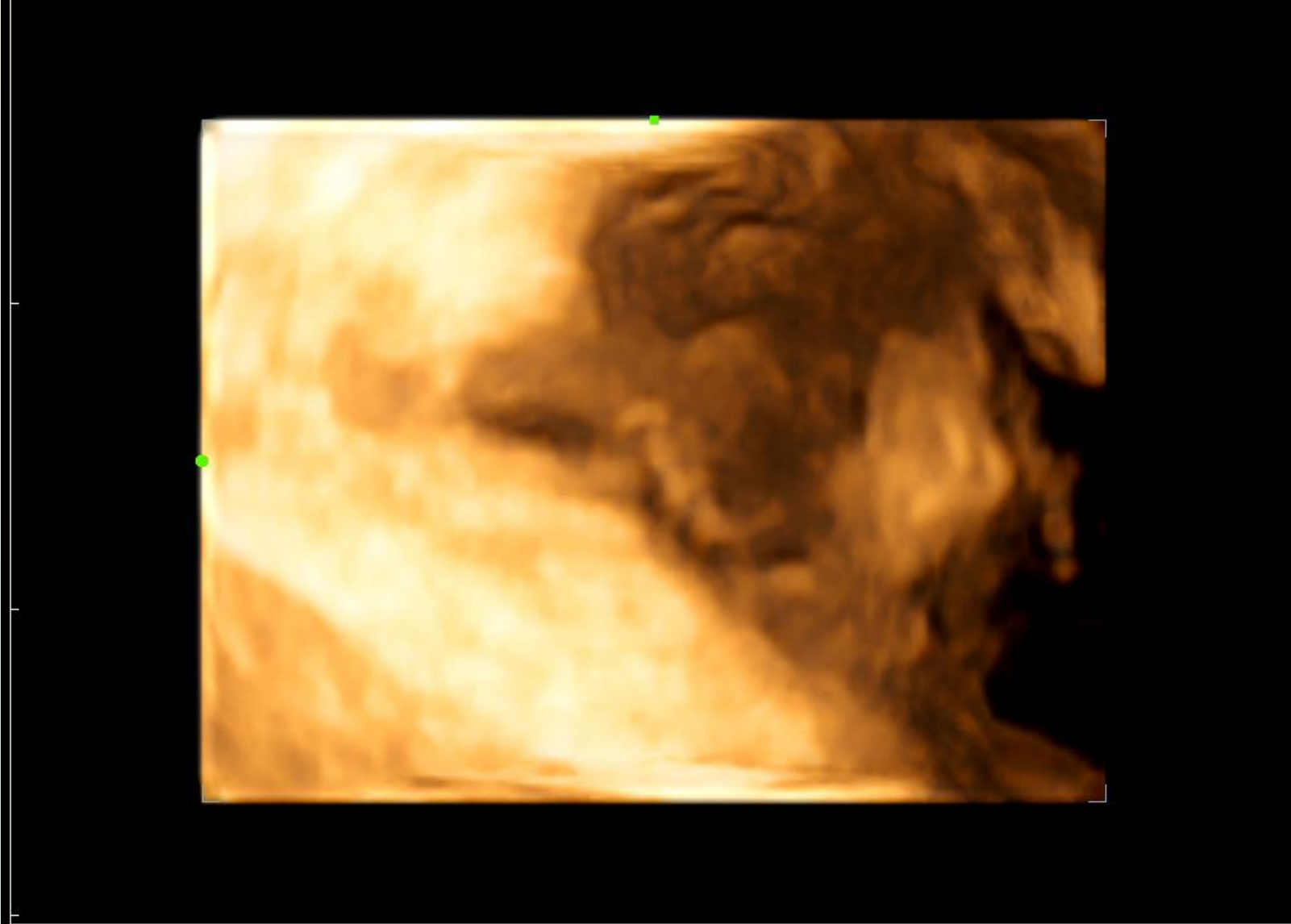
DC-8 EXP

B
F 3.2~7.9
D 7.0
G 59
FR 26
DR 120
iClear 3
iBeam 1



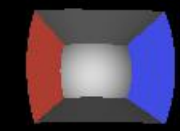
2 Dist 44.8 mm

AP 96.6% MI 0.8 TIS 0.2



DC-8 EXP

4D
Q high1
A 80°
G 59
T 38%
S 8
C 50%
B 54%
O 70%
VPS 1.8
Surface



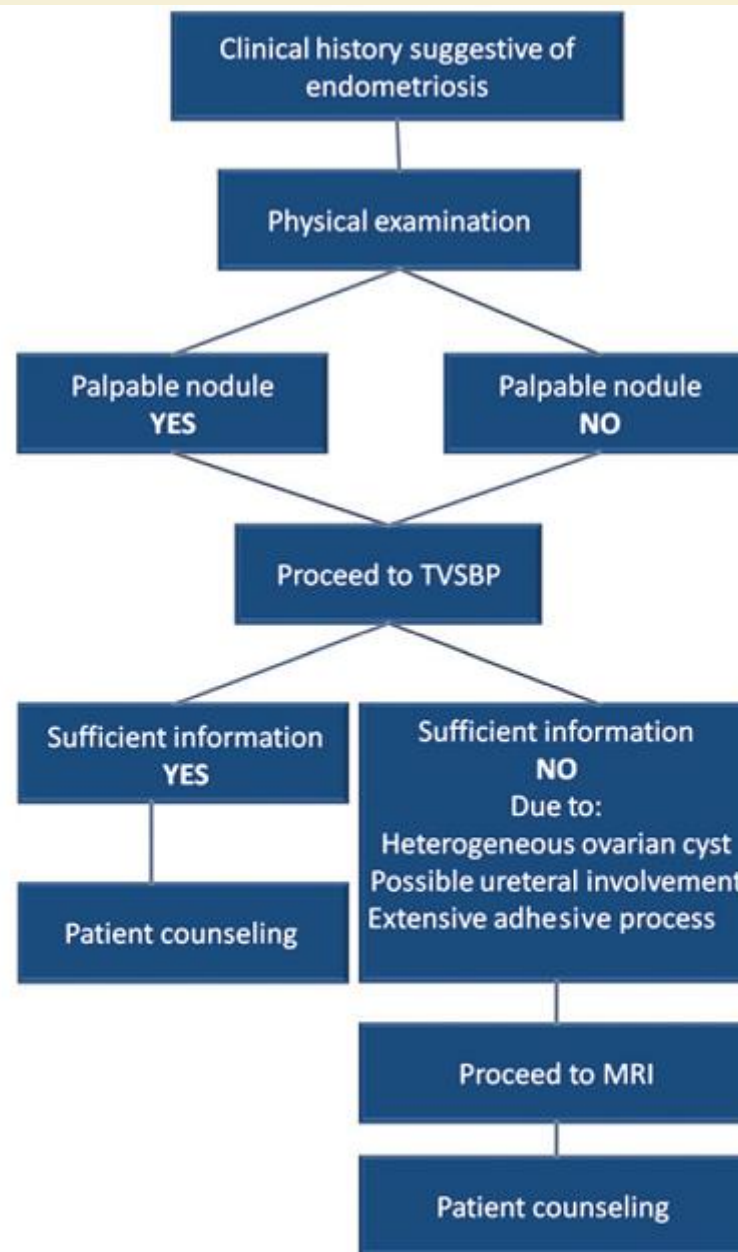


Figure 28. Flow chart depicts the algorithm for imaging evaluation of endometriosis. *MRI* = MR imaging, *TVSBP* = transvaginal US after bowel preparation.



Table 2 Performance of clinical examination, transvaginal sonography (TVS), saline contrast sonovaginography (SCSV) and magnetic resonance imaging (MRI) in discrimination of location of deep posterior endometriotic nodules

<i>Parameter</i>	<i>Clinical examination</i>	<i>TVS</i>	<i>SCSV</i>	<i>MRI</i>
<i>Vaginal fornix</i>				
Sensitivity (%)	57.9	57.9	94.7	73.1
Specificity (%)	88.6	91.4	97.1	94.3
PPV (%)	73.3	78.6	94.7	87.5
NPV (%)	79.5	80.0	97.1	86.8
LR+	5.065	6.75	33.157	12.89
LR-	0.475	0.46	0.054	0.279
<i>Uterosacral ligaments</i>				
Sensitivity (%)	55.6	55.6	88.9	66.7
Specificity (%)	80.0	95.6	95.6	95.6
PPV (%)	35.7	71.4	80.0	75.0
NPV (%)	90.0	91.5	97.7	93.5
LR+	2.77	12.5	19.99	14.99
LR-	0.55	0.465	0.11	0.34
<i>RVS involvement</i>				
Sensitivity (%)	58.3	63.9	80.6	83.3
Specificity (%)	83.3	88.9	100	77.8
PPV (%)	87.5	92.0	100	88.2
NPV (%)	50.0	55.2	72.0	70.0
LR+	1.75	5.75	∞	5.95
LR-	0.25	0.41	0.194	0.34

Table 3 Performance of transvaginal sonography (TVS), saline contrast sonovaginography (SCSV) and magnetic resonance imaging (MRI) in evaluation of bowel infiltration by deep endometriotic nodules

<i>Parameter</i>	<i>TVS</i>	<i>SCSV</i>	<i>MRI</i>
Sensitivity (%)	33.3	66.7	66.7
Specificity (%)	91.7	93.8	95.8
PPV (%)	33.3	57.1	66.7
NPV (%)	91.7	95.7	95.8
LR+	4.0	10.66	16.0
LR-	0.727	0.355	0.347

LR+, positive likelihood ratio; LR-, negative likelihood ratio; NPV, negative predictive value; PPV, positive predictive value.

Table 1 Performance of clinical examination, transvaginal sonography (TVS), saline contrast sonovaginography (SCSV) and magnetic resonance imaging (MRI) in the detection of posterior deep pelvic endometriosis

<i>Parameter</i>	<i>Clinical examination</i>	<i>TVS</i>	<i>SCSV</i>	<i>MRI</i>
Sensitivity (%)	87.0	73.9	93.5	91.3
Specificity (%)	75.0	87.5	87.5	75.0
PPV (%)	95.2	97.1	97.7	95.5
NPV (%)	50.0	36.8	70.0	60.0
LR+	3.48	5.91	7.47	3.65
LR-	0.17	0.29	0.07	0.11

LR+, positive likelihood ratio; LR-, negative likelihood ratio; NPV, negative predictive value; PPV, positive predictive value.

Table I. The sensitivity, specificity and LR with the 95% CI of modified transvaginal ultrasonography for the five considered locations.

Site	Specificity, % (n), 95% CI, %	Sensitivity, % (n), 95% CI, %	LR+95% CI	LR-95% CI
Vaginal involvement	89 (48/54), 83-97	91 (31/34), 79-97	8.21, 3.83-18	0.1, 0.03-0.29
Rectosigmoid involvement	92 (45/49), 37-61	67 (26/39), 55-73	8.17, 3.11-21	0.36, 0.23-0.57
Uterosacral ligaments involvement	94 (60/64), 92-100	50 (12/24), 34-60	8, 2.86-22	0.53, 0.36-0.80
Rectovaginal septum involvement	88 (37/42), 77-95	74 (34/46), 64-80	6.21, 2.68-14	0.3, 0.18-0.49
Anterior pouch (vesical and/or anterior) involvement	100 (70/70), 93-100	33 (6/18), 14-59	Infinity, 2.86-825	0.67, 0.48-0.92
Bladder involvement	100 (84/84), 94-100	100 (4/4), 40-100	Infinity, 9.50-2464	0, 0.01-1.40

Table II. The assessment of pelvic endometriosis by transvaginal sonography for some locations reported in the literature with the related prevalences.

Site	Authors	Sensitivity %	Specificity %	Prevalence %
Uterosacral ligaments involvement	Bazot <i>et al.</i> (2007a,b)	81	75	90
	Bazot <i>et al.</i> (2004a,b)	71	96	50
	Bazot <i>et al.</i> (2003)	75	83	81
	Present study	50	94	27
Vaginal involvement	Bazot <i>et al.</i> (2007a,b)	50	96	32
	Bazot <i>et al.</i> (2004a,b)	29	100	12
	Bazot <i>et al.</i> (2003)	25	100	13
	Present study	91	89	39
Rectovaginal septum involvement	Bazot <i>et al.</i> (2007a,b)	11	100	11
	Bazot <i>et al.</i> (2004a,b)	29	100	6
	Abrao <i>et al.</i> (2007)	98	100	51
	Present study	74	88	52
Rectosigmoid involvement	Bazot <i>et al.</i> (2007a,b)	93	100	67
	Bazot <i>et al.</i> (2004a,b)	87	97	35
	Bazot <i>et al.</i> (2003)	95	100	73
	Abrao <i>et al.</i> (2007)	98	100	39
	Present study	67	92	44

Table II Comparison of diagnostic performance of 2D and 3D ultrasound for endometriosis in the recto-sigmoid location.

	2D	3D
Specificity, % (n), 95% CI, %	93% (116/125) (89–95%)	97% (121/125) (93–99%)
Sensitivity, % (n), 95% CI, %	95% (73/77) (88–98%)	91% (70/77) (84–94%)
Positive predictive value % (n), 95% CI, %	89% (73/82) (83–92%)	95% (70/74) (88–98%)
Negative predictive value % (n), 95% CI, %	97% (116/120) (93–99%)	95% (121/128) (91–96%)
LR+ 95% CI	13 (7; 25)	25 (11; 75)
LR– 95% CI	0.06 (0.02, 0.15)	0.09 (0.05, 0.19)

Table III Comparison of diagnostic performance of 2D and 3D ultrasound for endometriosis in other posterior locations.

	2D	3D
Specificity, % (n), 95% CI, %	88% (98/111) (82–93%)	94% (104/111) (89–97%)
Sensitivity, % (n), 95% CI, %	71% (65/91) (64–77%)	87% (79/91) (81–91%)
Positive predictive value % (n), 95% CI, %	83% (65/78) (75–90%)	92% (79/86) (86–96%)
Negative predictive value % (n), 95% CI, %	79% (98/124) (74–83%)	90% (104/116) (85–93%)
LR+ 95% CI	6.10 (3.60, 10)	14 (6.69, 28)
LR– 95% CI	0.32 (0.23, 0.45)	0.14 (0.08, 0.24)

